

WILSON'S DISEASE IN MALTA

REPORT OF TWO CASES TREATED WITH PENICILLAMINE

LUIS VASSALLO,

B.Sc., M.D., F.R.C.P. (Ed.), M.R.C.P (Lond.), M.R.C.P. (Glasg.)

Consultant Physician, St. Luke's Hospital

Lecturer in Medicine and Pharmacology,

Royal University of Malta.

Summary

Two cases of Wilson's disease occurring in the Maltese Islands are described and their response to Penicillamine therapy together with various aspects of Penicillamine therapy discussed. The first case is particularly interesting as dramatic clinical recovery occurred in spite of seven years of complete incapacity from the disease, implying that the neurological disturbance in Wilson's disease is always potentially reversible, however severe the degree and prolonged the duration of the initial incapacity before therapy is started.

The term hepato-lenticular degeneration, as a synonym for Wilson's disease was coined by Hall in 1921, ten years after the epoch making description of the disease by Kinnier Wilson. Though the excess of copper in the liver of these patients had been noted as early as 1913 by Rumpel, this worker was more impressed by the amount of silver in the tissues. It was Cumings who in 1948 established beyond doubt the presence and importance of abnormal copper metabolism in this illness. The disease has been regarded as being excessively rare but with the discovery of many new cases, the incidence is now known to be much higher than had previously been calculated. Two patients are described below and observations are made on the prevalence of the disease in the Maltese Islands, and on the effect of treatment on the disease. The case of the first patient described is particularly interesting because in spite of the long duration of seven years of total incapacity before Penicillamine therapy was started,

the degree of clinical recovery has been remarkable.

Case 1

L.S., an unmarried female of 32, and one of the offspring of a first cousin marriage was first seen at home in March 1965. She gave a history of seven years total physical incapacity resulting from very gross involuntary movements affecting the limbs and trunk.

Her illness had started at the age of 18. The first symptom noted was that of tremor affecting the right hand, developing one night when she was on night duty as a nurse at a local hospital. The tremor was aggravated by intentional movements and became rapidly worse in the next few weeks, during which time her left hand also began to tremble. The tremor was coarse in nature. Coarse involuntary movements soon affected the trunk and lower limbs and within six months of the onset of her illness she had become completely bedridden as the slightest attempt at purposeful voluntary movement resulted in gross accentuation of the violent tremor. Feeding and drinking without help became impossible. Her mental faculties did not appear to be affected and she showed no emotional lability. Her general condition had remained static through all the intervening years. She claimed that early in the course of her illness marked photophobia was present as was continuous pain in the cubital and popliteal fossae. She had been seen over the years by various doctors and various remedies had been prescribed. Even hypnosis had been tried after the diagno-

sis of hysteria had been made by a specialist.

Her past medical history was unremarkable. She had suffered from the usual childhood illnesses. There had never been any liver disorder or history of haematological trouble.

Family history

Her mother was in good health. Her father had diabetes mellitus and had suffered from jaundice as a young man. A ten-year old brother of the patient had died in hospital because of haemolytic anaemia of unknown cause. An elder sister was alive and apparently normal while another brother was still alive though mentally retarded.

On examination, the patient appeared well built and obese and showed constant violent shaking of the limbs and trunk. Her heart rhythm was normal and her blood pressure was 150/90. The patient was very cooperative and appeared of normal intelligence and not confused. No hepatomegaly or splenomegaly could be elicited. On examination of her central nervous system, very prominent Kayser Fleisher rings in both eyes were present. There were no other cranial nerve abnormalities. She talked in a very staccato manner. Titubation of the head was severe. Very gross static and intention tremor together with dysidiadokinesia in

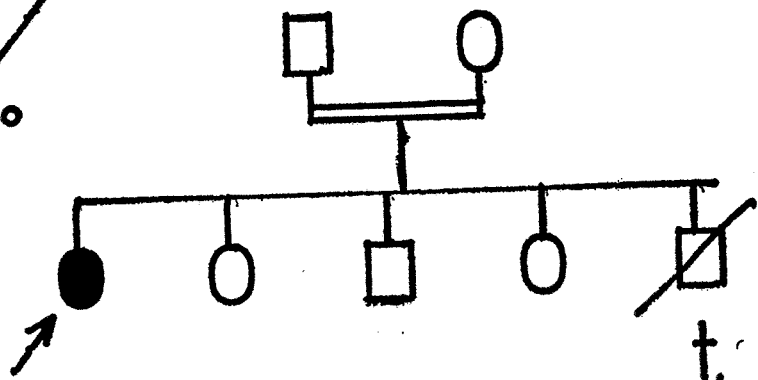
both upper limbs was seen. Moderate cogwheel rigidity at the elbows and wrists could be felt. Violent involuntary movements were also present in the lower limbs as was moderate cogwheel rigidity. Tendon reflexes were exaggerated in all four limbs. Both plantar responses were flexor. There was no obvious weakness in the limbs and it was apparent that physical incapacity was totally related to the gross tremor. No abnormalities of her sensory modalities could be demonstrated. The patient could only stand up with the greatest difficulty because of lurching from the severe tremor. Physical examination showed no other abnormalities. Breasts were normally developed. No abnormalities of the nail beds were seen.

Investigations included: Hb. 14.5g/100 ml.; RBC 5,190,000/c.mm.; platelets 58,000/c.mm.; blood film: no abnormality; blood urea 32 mgm%. Her serum bilirubin was 1.1mgm/100ml.; the van den Bergh reaction was indirect; SGPT: 171.U./litre; serum alkaline phosphatase 9 units/100ml. The serum calcium level was 5.5 mEq. / litre; plasma inorganic phosphate 2.3mgm./100ml. Serum uric acid was 4.2mgm/100 ml. The prothrombin time was 18 seconds (control 15 secs.). The Coombs test was negative. The RPCF, Wassermann and Kahn tests were negative. Serum protein electrophoresis showed the following percentages: albumin 39: a₁ 6; a₂ 7; b 14; globulin 34%.

Propositus ↗

dead ↘

st.birth ○



Family 1

24 hour urinary excretion of glucose was 0 g., while that of uric acid was 1.42g. X-rays of the knees and elbows showed no abnormalities. Serum copper and serum caeruloplasmin levels were not performed at the time for technical reasons though later figures (*see below*) are available.

On 22.4.65, the patient was started on D-Penicillamine in a dose of 300mgm. four times daily. On 1.5.65, the patient developed a temperature of 102°F and a severe generalised urticarial rash. Penicillamine was stopped the next day and Benadyrl 25 mgm. twice daily given. The rash and temperature subsided after three days and on 7.5.65, Penicillamine was re-started in a dose of one capsule (150mgm.) daily. As there was no recurrence of temperature and rash and no evidence of other toxic side effect, Penicillamine was gradually increased in dose every few days till she was having 8 capsules daily (1200 mgm.) by the 29.5.65. Penicillamine was increased to 10 tablets daily (1500 mgm.) on 16.6.68 and this dose was adhered to, over the next few months. The patient was kept in hospital under observation till 29.6.65, when she was discharged home with a view to reassessment after a few months. At the time of her discharge, no evidence of clinical improvement could be detected, nor was there any further clinical deterioration.

She was readmitted on 20.9.65 for review. She now appeared clinically much better. Amelioration of her symptoms had started about three weeks before. The gross intention tremor of the upper limbs had diminished and she was now starting to walk slowly and unaided for the first time in seven years. Ataxia, however, was still very evident. The severe dysarthria had also improved. A repeat blood count showed no change apart from a rise in her platelet count to 250,000 c.mm. Liver function tests showed a serum bilirubin of 0.9 mgm./100 ml.; a SGPT of 15 I.U./litre and a serum alkaline phosphatase of 18.7 K.A. units/100ml. There was no proteinuria nor were there any renal casts. The regime of 1200 mgm. of Penicillamine daily was continued. When reassessed again in

January 1966 (eight months after starting Penicillamine) the change in the clinical picture was remarkable. Gait was now practically normal and the only noticeable abnormality was slight titubation of the head and trunk, and minimal intention tremor of the hands. She could now carry out all ordinary physical activities and household duties and often went out for long walks alone to neighbouring villages. The Kayser Fleischer rings, though still present were far less evident. Her clinical condition over the last six years has shown further improvement. Tremor of the limbs is only intermittent and mild, and is only evident when she is excited. Her intellectual faculties appear normal and there is no abnormality of affect. Her neurological functional disturbance is therefore now, according to the classification of Goldstein and his colleagues, (1962), Grade 1, whereas her former clinical grading according to the same system was Grade 4.

She is at present on Penicillamine, 1050 mgm. daily. She has been on Penicillamine now for over seven years.

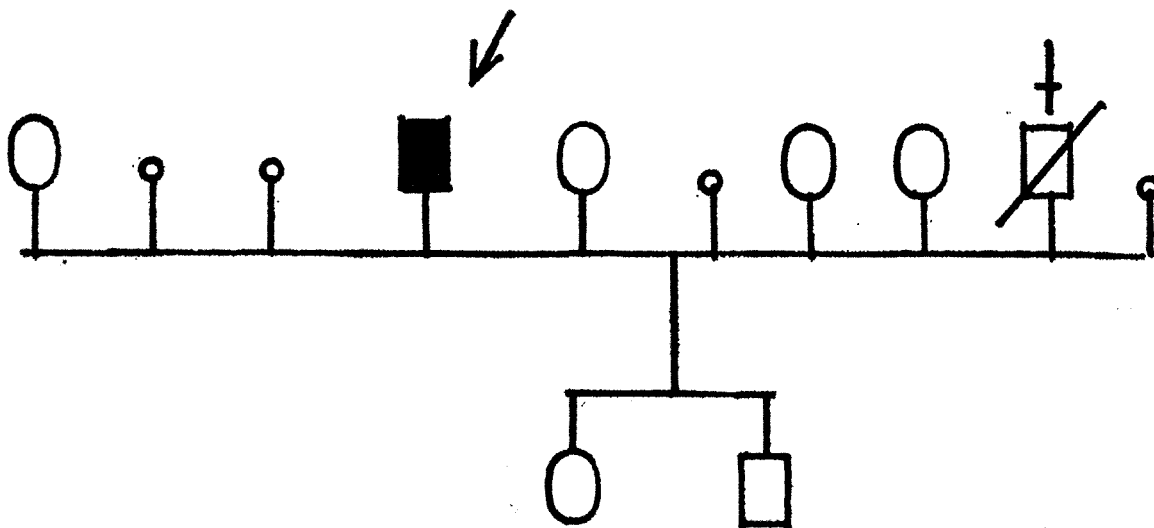
On 8.6.68, the following estimations were made:

Serum Copper 46 ug/100 ml. (70-165 normal)
 Caeruloplasmin 5.87 mg/10 ml. (0.5-5.0)
 Urinary Copper 87 ug/24 hrs. (1-100)

Case 2

A 19 year old Maltese male, J.C., was referred by his doctor for a second opinion, because of involuntary movements, which were especially noticeable when the patient became excited. The first symptoms had started about six months previously as the patient was voluntarily swaying his body while listening to a favourite piece of "pop"-music. He found that he could not stop the rhythmic movements completely when the music record stopped. His doctor at first thought that the symptoms were purely psychological and prescribed a small daily dose of phenobarbitone. A second opinion was sought, however, when the symptoms began to deteriorate in spite of treatment.

When seen as a hospital outpatient (22.3.67), the only abnormality detected



Family 2

was the mild rhythmic movements of the trunk together with some head titubation. Only minimal static tremor of the outstretched arms could be detected. There was no intention tremor. The patient had no dysarthria. A faint Kayser Fleischer ring was bilaterally present. The cranial nerves were normal. The tendon reflexes were also normal and both plantar responses were flexor. There was no hepatomegaly or splenomegaly. The rest of physical examination was normal.

Family History:

He was the seventh offspring of a nonconsanguineous marriage. The second offspring — a male — had died at the age of nine after developing jaundice and ascites as a complication of an obscure liver disorder.

He was admitted to hospital for further investigation. The presence of the Kayser Fleischer rings was confirmed by slit lamp microscopy. The blood count was normal. The serum bilirubin was 0.5mgm./100ml.; the van den Bergh reaction negative; serum GPT 10 I.U./litre. The Bromsulphthalein test showed 43% retention. Serum calcium was 5.5 mEq./litre; Plasma inorganic phosphate: 3.1 mgm./100ml. The serum uric acid was 4.2mgm./100ml. Urinary uric acid was 0.44g. per 24 hrs. The total serum pro-

teins were 7.8 g./100 ml., of which 4.4g. were albumin. X-rays skull was normal as was a skeletal survey.

There was a delay of four weeks in obtaining Penicillamine supplies for treatment. Treatment was started with an initial dose of 1200mgm. D-Penicillamine daily. No toxic side effects were observed. During the week prior to Penicillamine treatment, there was further noticeable clinical deterioration. His gait became ataxic for the first time and the head titubation worsened considerably. The first beneficial effects (clinically) of Penicillamine became obvious about eight weeks after the start of therapy. Gradual regression of his symptoms then began.

At the present time all the abnormal neurological signs have disappeared, with the sole exception of the Kayser Fleischer rings, which are still present though very faint.

His neurological functional disturbance is therefore Grade 0 (Goldstein *et al.* 1962), whereas the functional disturbance at the start of treatment was Grade 1.

The patient was at first on a maintenance dose of D-Penicillamine (1500 mgm.) daily but the dose has now been curtailed to 900 mgm. daily. He is completely symptom free.

On 15.6.67, the following estimations were made:

Serum Copper 76.1 ug/100 ml.
 Caeruloplasmin 14.1 mg/100 ml.
 Urinary Copper 104 ug/24 hrs.

Discussion

These cases are the first reported cases occurring in the Maltese Islands. Though Wilson's disease has a wide geographic distribution and has been described in individuals of many races and countries including Negroes, Indians, Chinese, Malaysians, Japanese and Eskimos (Boudin & Pepin, 1959; Cumings, 1959), it has never been previously reported in Maltese patients. This is surprising because the region of Sicily and the extreme tip of Italy is held to be one of the geographical areas in Europe where Wilson's disease occurs with unusually high incidence. Thus Bearn (1960) in his study of thirty families in New York City, in whom Wilson's disease had been discovered, found that seven of them originated from Sicily and Southern Italy. Another area, where many cases of Wilson's disease have been found is Eastern Poland. It has been suggested that the original mutations in Eastern Poland and Sicily were not identical as the patients of Sicilian origin had an earlier age of onset, more severe symptoms, more hepatic involvement and more abnormality of serum copper and caeruloplasmin levels.

The relative severity of involvement of the brain and liver in different families has also been interpreted as a further indication of genetic heterogeneity in Wilson's disease and the family with three sibs showing severe liver cirrhosis without neurological signs described by Fisher and Sherlock (1964) has been quoted in favour of this hypothesis.

Considerable migration into Malta from Sicily has occurred over the centuries and it is therefore reasonable to suppose *a priori*, that a higher prevalence than usual (albeit undetected) of Wilson's disease exists in the Maltese Islands. This is all the more likely in view of increased incidence of consanguinity that exists in some of the more isolated areas of the Maltese Islands.

The effect of increased consanguinity rate in geographical isolates has perhaps been best illustrated in the case of Wilson's disease in the Ards Peninsula of Northern Ireland where the gene carrier incidence of this recessive disease has been estimated as approximately 1 in 40 (Warnock, 1961). Other factors affecting the known prevalence of such a disease in a geographical region, are clinical diagnostic awareness and the availability of specialised laboratory procedures in establishing the diagnosis. In places where laboratory facilities are difficult, it is only possible to have an unconfirmed diagnosis if the disease presents in an unusual way and if Kayser Fleischer rings are not present. A Kayser Fleischer ring is the only pathognomic sign of the disease and its demonstration obviates the need of laboratory procedures as the diagnosis of Wilson's disease can be made at the bedside outside hospital (Warnock, 1961).

Two families have been discovered in Malta with affected individuals. Only two affected individuals are living as the other two siblings strongly suspected of having had the undiagnosed disease died in late childhood a few years ago. One died of liver disease complicated by ascites while the other died of acute haemolytic anaemia — again a well known form of presentation of Wilson's disease.

The two affected individuals from different families presented with neurological manifestations. It is interesting to note that the suspected siblings who died, had different types of the disease, and are therefore exceptions to the generalisation that the disease in any one sibship conforms to a distinctive clinical pattern. These findings cannot be held in favour of the different patterns of the disease depending on the geographical region where the individuals originate. One can only state that till analysis of large clinical samples become available in due course, such views can only be regarded as conjectures.

The prevalence of the disease in the Maltese Islands is therefore about 1 in 150,000 of the population. If the two dead siblings who in all probability had undiagnosed Wilson's disease are also in-

cluded, then the prevalence would be about 1 in 75,000. The true prevalence is most likely greater than this figure, and the next few years should uncover more cases. It is of interest that one patient is the offspring of a first cousin marriage while the parents of the other family are totally unrelated. Bearn (1960) showed that the frequency of consanguineous matings (first and second cousins) among the parents of thirty sibships with Wilson's disease was about 46%. It can be taken as an approximate rule that about half the families with Wilson's disease show evidence of consanguinity. In 1961, Bearn calculated that the overall gene frequency rate is of the order of 1 in 500, thus giving rise to a disease incidence of 1 in 1,000,000 of the population. In the last few years, because of the increasing focusing of attention on the disease and the discovery of many fresh cases, the reported incidence has risen. Among the countries where a relatively high incidence has been reported is Rumania where it is now about 1 in 100,000 (Kreindler, Ionescu, Drinca-Ionescu, 1964).

Perhaps one of the most striking clinical features in one of the patients described above is the fact that there had been seven years' total incapacity before treatment with Penicillamine was instituted. The introduction of Penicillamine (b, b-dimethyl-cysteine hydrochloride) as a copper chelating agent in Wilson's disease by Walshe in 1956, is one of the most important landmarks in the history of the illness. Its beneficial effects have been increasingly recognised over the past few years and it is now the drug of choice. BAL, which was introduced by Cumings in 1948, has been mostly superseded though an authority such as Kelly (1958) felt that the clinical results obtained after BAL therapy were superior to those of Penicillamine. It is well known that cases of Wilson's disease showing total disablement have recovered dramatically after treatment with Penicillamine. Thus nine of a series of fourteen patients described by Walshe, having neurological involvement and showing severe or total disability, became virtually symptom free after two or three years of uninterrupted therapy.

What is most unusual, however, is the dramatic extent of recovery after such a long time (seven years) of total disability as demonstrated in the Maltese patient described. As far as can be ascertained, none of Walshe's nine patients in that particular series, who made a good recovery had been totally disabled for such a long time. Walshe thought it problematical whether the patient he mentioned with a twenty year history of ataxia would ever make a really useful recovery.

Some indirect implications therefore arise regarding the prognosis in treatment and also regarding the mechanism of copper deposition in the tissues. It has been established that excess copper is always associated with the development of clinical symptoms in untreated cases though the time factors involved in the deposition of copper are unknown. The exact mechanism for copper deposition are moreover still a matter of controversy. Uzman's postulate (1957) of an abnormal protein with an undue affinity to copper as the essential defect in Wilson's disease is now considered untenable (Gibbs and Walshe, 1966). Broman (1964) has put forward an almost opposite theory. He claims that it is the deficiency of the transport protein caeruloplasmin serving as a carrier of a copper containing prosthetic group which leads to brain damage. This prosthetic group normally acts as an oxygen activating unit in cytochrome c oxidase according to Broman. In the case of the liver, damage is due to a direct toxic action of copper on the cells. Others hold that the brain damage results from an obscure form of liver dysfunction, as evidence of microscopical damage from copper deposition is more controversial. Up to the present time the exact rôle of the mysterious transport protein caeruloplasmin in copper metabolism is still unknown.

The first patient illustrates the fact that even after seven years of functional incapacity from the disabling straight-jacket of copper deposition, no irreversible structural damage must of necessity be presumed. It is therefore essential to pursue full energetic treatment in spite of apparent initial lack of response for many months. The delay of several months

before clinical improvement is noticed after the start of Penicillamine may lead to discontinuation of the drug and its substitution by a less satisfactory chelating agent such as BAL, if this delay in clinical improvement is not fully appreciated by the clinician. The first case described above illustrates this point. It is strongly suspected by the author that opinions expressed in the past by some workers in favour of BAL therapy as against Penicillamine were based on inadequate duration of Penicillamine therapy. The delay in clinical improvement after the administration of Penicillamine, was also stressed by Richmond, Rosenoer, Tompsett, Draper, and Simpson (1964). In Case 2 of the three cases they described, the drug was temporarily abandoned in favour of dimer-caprol (BAL) because of the belief that Penicillamine was not having any effect. In their first case, little change was seen for about two months.

Another important facet shown by the first patient concerns the initial toxic side effects of Penicillamine that may occur, only a few days after the administration of this drug. These initial toxic reactions may trap the unwary physician into stopping Penicillamine therapy permanently in such a patient. It is important to emphasise that the duration of this drug reaction is only temporary. The first patient above described developed the drug skin rash about a week after the drug was started. This happening has also been previously reported in the literature. Thus, a skin rash developed on the 8th to 10th day of treatment in five out of sixteen patients treated for cystinuria, by MacDonald and Fellers (1966). In three of these patients the drug was restarted in small doses after a week and increased gradually until the original dose was reached, no further complications occurring. Another method used in one of their patients was the administration of an initial dose of 100mgms. of Cortisone acetate intramuscularly followed by 10mgms. of Prednisone daily for five days. The steroid dosage was then gradually reduced during the following week. The development of this acute sensitivity reaction has been observed in about one third of patients

treated with Penicillamine (Sternlieb and Scheinberg 1964).

Other undesirable side-effects may arise through Penicillamine. Occasionally, there may be a transient optic neuritis (Tu, Blackwell and Lee, 1963). The most serious reaction is the development of the nephrotic syndrome (Fellers and Shahidi, 1959). Death may occasionally occur (Yonis and Karp, 1963). Sternlieb holds the view that only patients receiving the racemic or DL form of Penicillamine develop this complication (Sternlieb, 1966), and that no cases have been recorded in patients receiving D-Penicillamine which is the form commonly used nowadays. Rosenberg and Hayslett (1967) however reported nephrotoxic effects with D-Penicillamine in three patients suffering from cystinuria. The toxic effects regressed three to six months after cessation of treatment; renal biopsies in each of their patients showed a distinct focal glomerulitis.

There does not seem to be any marked anti-pyridoxine activity of D-Penicillamine as has been reported for L-Penicillamine (Kuschinskas and du Vigneaud, 1957). L-Penicillamine is a potent antagonist of pyridoxine combining with pyridoxal to form a thioxolidine. It is however advisable with prolonged administration of the drug to add pyridoxine supplements. In case I, the complaint of aches and pains in the lower extremities together with a feeling of pins and needles promptly disappeared with the exhibition of Pyridoxine 20mgms three times daily.

These observations on the toxicity of Penicillamine are all the more relevant in view of the controversial authoritative paper by Sternlieb and Scheinberg (1968), backed by Walshe (1968) urging treatment of all asymptomatic subjects in whom a biochemical diagnosis of Wilson's disease has been reached.

A clinical feature common to the two patients above described is the rapid deterioration in neurological function, once symptoms had appeared. The first patient was completely incapacitated within six months of the onset of symptoms. The deterioration in gait and trunk tremor within one week in the second patient,

who was admitted for observation and investigation while supplies of Penicillamine were awaited, was striking. The clinical deterioration may be so rapid that the true diagnosis may not be suspected. Thus one of the original diagnoses in Case I was that of an acute encephalitis.

The system used in grading the degree of clinical neurological disturbance in Wilson's disease, by Goldstein, Randall, Gross, Rosevear and McGuckin (1962) should be more widely adopted by other workers in the field as it helps to standardise the amount of clinical disability present and the response to therapy. Goldstein and his colleagues propose five categories. Patients are classed as Grade 0, when no symptom or sign is noticeable to the patient; Grade 1, when there are minimal but definite signs or symptoms; Grade 2, when the signs are moderate but the patient is still able to work at his usual job; Grade 3, when there are severe symptoms or signs and the patient is unable to work at his job but is at least partly able to walk, write, dress and feed himself; Grade 4, — the most severe grade — with incapacitating symptoms, preventing the patient from walking, writing, dressing or feeding himself, and keeping the patient bedridden. This system of clinical assessment is particularly useful in comparing the effects of therapy both in the same and in different series, and should yield over the years valuable information. It is suggested that this subject of clinical classification with an extension to deal with liver damage should be discussed by the different authorities on Wilson's disease and that an international classification be agreed upon.

Acknowledgements

My grateful acknowledgements are due to the staff of the Pathology Department at St. Luke's Hospital for carrying out the laboratory tests, the staff of the Radiology Department for the radiological studies, and to Prof. A. P. Jaccarini for the carrying out of the caeruloplasmin and

copper studies.

My thanks are also due to Drs. E. P. Gatt and J. Xuereb for referring the patients.

References

- BEARN, A.G. (1960), *Ann. Human Genet.*, **24**, 33.
 BOUDIN, G. and PEPIN, B., "Degenerescence hepatolenticulaire" Masson et Cie, Paris. 1959.
 BROMAN, L. (1946), *Acta Soc. Med. Upsal.*, **69**, Suppl. 7.
 CUMINGS, J.N. (1948), *Brain* **71**, 410.
 CUMINGS, J.N. (1959), "Heavy metals and the brain". Oxford.
 FELLERS, F.X. and SKADIDI, N.T. (1959) *Amer. J. Dis. Child.*, **98**, 669.
 FISHER, M.M. and SHERLOCK, S. (1964), *Arch. Dis. Childh.*, **39**, 14.
 GIBBS, K. and WALSUE, J. M. (1966) *Lancet*, **1**, 175.
 GOLDSTEIN, N.P., RANDALL, R.V., GROSS, J.B., ROSEVEAN, J.W., and MCGUCKIN, W.F. (1962), *Neurology (Minneapolis)*, **12**, 231.
 HALL, H. C. (1921), *La degenerescence hepatolenticulaire; Maladie de Wilson pseudosclerose*; Masson et Cie, Paris. 1921.
 KELLY, R. (1959) in Cumings, J. N. and Kremer, M. (ed.), "Biochemical Aspects of Neurological Diseases", Blackwell Scientific, Oxford p. 113.
 KREIDLER, A., IONASESCU, V., and DRINCA-IONESCU, M. (1964), *Stud. Cercet. Neurol.*, **9**, 401-410 quoted by Pratt. R.T.C. "Genetics of Neurological Disorders". London. Oxford University Press 1967.
 KUCHINSKAS, E.J., and DU VIGNEAUD, V. (1957), *Arch. Biochem. Biophys.*, **66**-1.
 MACDONALD, W.B., and FELLERS, F.X. (1966), *J. Am. Med. Ass.*, **197**, 396.
 RICHMOND, J.A., ROSENBERG, V.M., TOMPSETT, S.L., DRAPER, I., and SIMPSON, J.A. (1964), *Brain*, **87**, 619.
 ROSENBERG, E. and HAYSLETT, R. (1967) *Asch. Dis. Child.* **42**, 682.
 RUMPEL, A. (1913), *Z. Nervenheilk.*, **49**, 54.
 SCHEINBERG, I.H., and STERNLIEB, I. (1959), *Gastroenterology*, **37**, 550.
 STERNLIEB, I. (1966), *J. Am. Med. Ass.* **198**, 1311.
 STERNLIEB, I., and SCHEINBERG, I.H. (1964), *J. Am. Med. Ass.*, **189**, 748.
 STERNLIEB, I., and SCHEINBERG, I.H. (1968), *New Eng. J. Med.*, **278**, 352.
 TU, J., BLACKWELL, R.Q., and LEE, P.F. (1963) *J. Am. Med. Ass.* **185**, 83.
 UZMAN, L.L. (1957), *Arch. Pathol.*, **64**, 464.
 WALSHE, J.M. (1956), *Amer. J. Med.*, **21**, 487.
 WALSHE, J.M. (1968), *New Eng. J. Med.*, **278**, 795.
 WARNOCK, C.G. (1961), p. 205 in Walshe, J.M. and Cumings, J.N. "Wilson's Disease" Blackwell Scientific Public. 1961.
 YONIS, I. Z. and KARP, M. (1963), *Lancet*, **2**, 689.