

# Ruptured abdominal aortic aneurysm with a horseshoe kidney: an uncommon but potentially troublesome coexistence

Nebojsa Petrovic, Stephen Micallef Eynaud, Sinisa Pejkic

## Abstract

We report a case of an elderly patient with a ruptured abdominal aortic aneurysm (AAA) associated with a horseshoe kidney (HSK) treated by an emergency open repair and discuss the anatomical features and surgical challenges attendant to this rare combined pathology.

## Introduction

Horseshoe kidney is the most frequent congenital renal malformation, with the prevalence in a general population of up to 0.25%.<sup>1</sup> It is characterized by the presence of an anomalous strip of tissue or *isthmus*, comprised in the vast majority of cases of a functional renal parenchyma, crossing in front of the abdominal aorta and interconnecting the two renal moieties at their inferior (~95% of cases) or superior poles; the least frequent variant of this fusion anomaly is a “cake kidney”, in which both the upper and the lower poles of the two kidneys are conjoined. Clinical significance of HSK includes frequent association with other congenital malformations, susceptibility to medical and surgical renal disease (e.g., nephrolithiasis, hydronephrosis, urinary tract infection), as well as posing technical difficulties during retroperitoneal surgical procedures, such as the abdominal aortic aneurysm repair.<sup>1-3</sup> Cases of HSK coinciding with a *ruptured* AAA, as described in this report, represent true surgical rarities.

## Case report

A 71-year-old man presented to Mater Dei Hospital Emergency Department four hours after a sudden onset of excruciating abdominal pain followed by a transitory syncope. Apart from being an ex-smoker, his past medical history was unremarkable and there was no family history of aneurysmal disease. On examination, his blood pressure was 102/53 mm Hg, heart rate 92 bpm and oxygen saturation 92% on room air. Routine laboratory investigations revealed a haemoglobin level of 125 g/L, haematocrit of 0.38 L/L, serum creatinine level of 211 µmol/L and eGFR of 22 mL/min/1.73m.<sup>2</sup> On palpation of abdomen, tender pulsating mass was noted around the umbilicus. In view of patient’s hemodynamic stability, *contrast-enhanced computed tomography (CT)* was urgently performed. It confirmed the diagnosis of an acute

### Nebojsa Petrovic\*

Vascular Surgery Department,  
Mater Dei Hospital  
Msida, Malta  
nebojsa.petrovic@gov.mt

### Stephen Micallef Eynaud

Cardiothoracic Surgery Department,  
Mater Dei Hospital  
Msida, Malta

### Pejkic Sinisa

Vascular Surgery Department,  
Mater Dei Hospital  
Msida, Malta

\*Corresponding Author

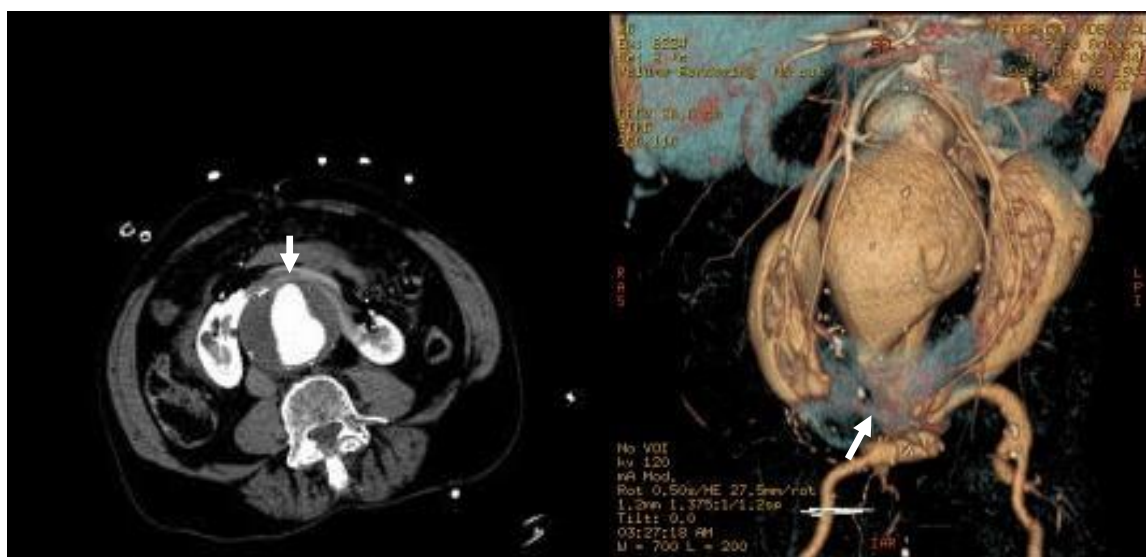
## Case Report

rupture of a large juxtarenal AAA measuring 9.6 cm in maximum transverse diameter (Fig. 1).

Patient was immediately taken to the operating theatre for an emergency open repair. After placing him under general anaesthesia, median laparotomy was performed and transperitoneal route used to approach the abdominal aorta. The findings of a large AAA surrounded by acute retroperitoneal hematoma (RPH) in combination with the HSK confirmed the preoperative diagnosis. After mobilization of the left hepatic lobe and systemic heparinization, supraceliac aortic cross-clamp was initially placed, followed by its prompt repositioning at infrarenal level once the distal duodenum was mobilized, the left renal vein identified and the short infrarenal aneurysmal neck dissected free. Both common iliac arteries were then exposed and cross-clamped after finding them to be moderately atherosclerotic but without aneurysmal lesions. Finally, HSK isthmus was carefully isolated and retracted away from the aneurysm, enabling us to proceed with the aortic repair. Upon longitudinal opening of the aneurysm sac and removal of a mural thrombus, laceration of the aneurysm left posterolateral wall was identified as the site of rupture. Aortic continuity was restored by interpositional grafting from infrarenal aorta to

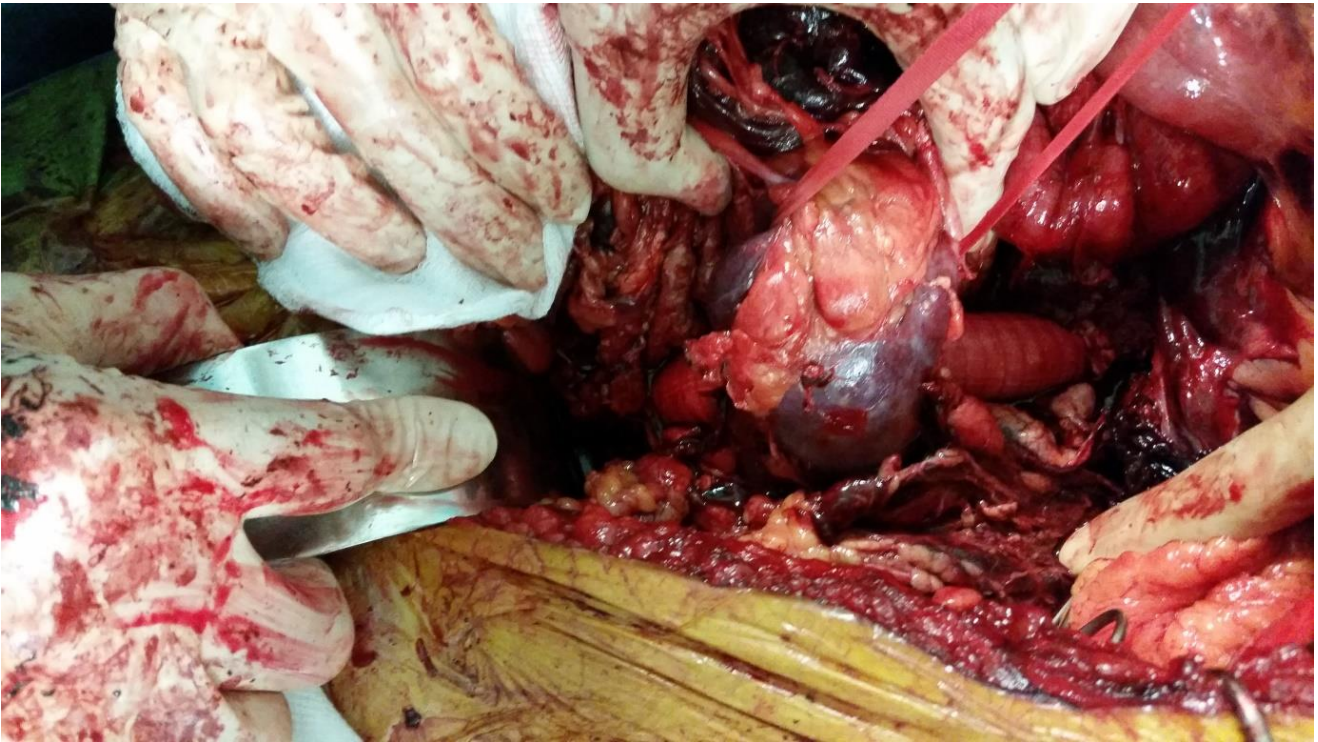
aortic bifurcation using the 20-mm polyester prosthesis tunnelled behind the preserved HSK isthmus (Fig. 2). Operative time was 125 minutes and blood loss 1700 mL, with intraoperative cell saver device usage enabling for 420 mL re-transfusion of autologous packed red blood cells. Patient tolerated the procedure well and was subsequently transferred to an intensive therapy unit in a hemodynamically stable condition. Postoperative course was marked by oliguria (30 mL/h while on inotropic support) and difficulty weaning from mechanical ventilation. Deteriorating renal function necessitated continuous renal replacement therapy. Follow-up CT performed at postoperative day 6 showed patent aortic graft with competent anastomoses and intact distal arterial system without embolism, but also revealed loss of normal parenchymal perfusion in relation to the lower pole of the left renal moiety, with the right renal moiety maintaining normal perfusion. The main renal arteries on either side appeared patent all the way down to the corresponding hila (Fig. 3). Unfortunately, patient expired of multiorgan failure on postoperative day 7.

**Figure 1:** Preoperative transverse tomogram (left, level of 4th lumbar vertebra) and 3D reconstructed CT image (right), showing 9.6-cm large juxtarenal AAA with surrounding massive acute RPH. Anteriorly displaced by the AAA and the RPH, HSK is present, with its isthmus connecting the two renal moieties inferior poles (arrows) and displaying decreased perfusion in comparison to the rest of the HSK. Apart from two normal renal arteries, a small accessory left renal artery arising from the aneurysm neck posterior wall and supplying the isthmus of HSK was also noted.

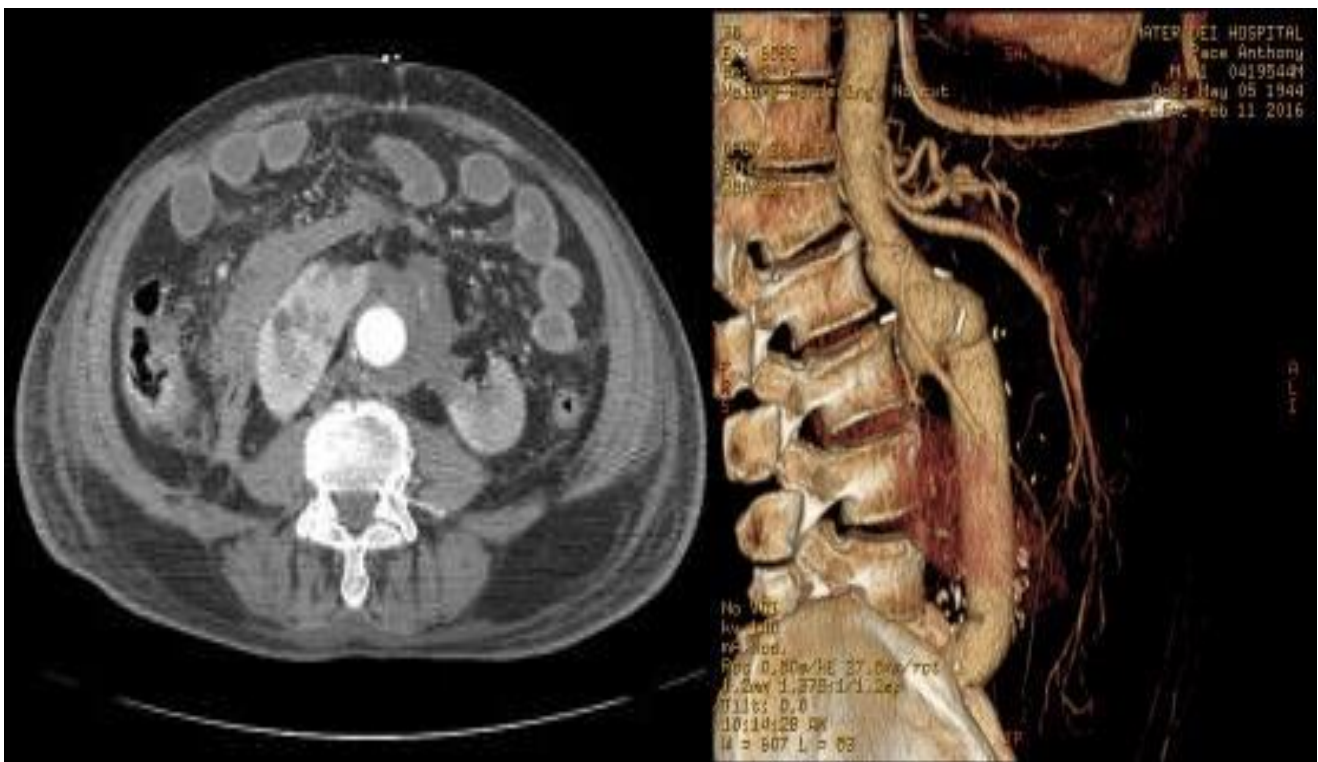


## Case Report

**Figure 2:** Intraoperative photograph after completing repair of ruptured AAA. Polyester aortic prosthesis is positioned behind the preserved HSK isthmus (retracted upward with umbilical tape).



**Figure 3:** Postoperative transverse tomogram (left) and 3D reconstructed CT image (right) show patent aorto-aortic graft with competent anastomoses and intact HSK isthmus.



### Discussion

Co-existence of HSK and AAA is estimated at 0.12% of patients undergoing elective open aneurysm repair.<sup>1</sup> It is characterized by the presence of: 1) renal isthmus, usually thick and parenchymatous, 2) anomalous renal vasculature, and 3) anteromedially displaced ureters.<sup>1-3</sup> Each of these anatomical peculiarities requires special attention during AAA open repair in order to avoid HSK-related postoperative complications, which can have catastrophic consequences. Since the first case of successful treatment of an aortic aneurysm in association with a HSK was reported by Phelan et al. in 1957,<sup>5</sup> the fascinating progress in the field of vascular surgery in general and better understanding of this combined pathology in particular have led to considerable improvements and shifts in its treatment. In a review article published in 2001, Stroosma et al.<sup>3</sup> found a total of 176 cases of AAA with HSK reported in the literature over the 44-year period (1956–1999), of which 42 were of ruptured AAA. Different reconstructive strategies were described, including: 1) transperitoneal approach with or without division of HSK isthmus, 2) retroperitoneal approach, and 3) endovascular aneurysm repair, with its first use in this situation reported in 1997 by Ferko et al.<sup>7</sup> From this collective experience, several important lessons have been learned. Preoperative CT with a contrast enhancement is the preferred diagnostic modality, raising awareness of the unusual situation and allowing for more deliberate planning of aortic reconstruction.<sup>1,3</sup> In an elective setting, when dealing with an asymptomatic aneurysm, endovascular repair (EVAR) or open surgical repair using the retroperitoneal approach to abdominal aorta offer clear advantages in avoiding or mitigating technical difficulties imposed by the aberrant anatomy.<sup>1,3,6,8</sup> General consensus is that minor accessory renal arteries (<3 mm) can be ligated/sacrificed without undue consequences, while more sizeable ones should be revascularized to avoid loss of renal parenchyma.<sup>1,3,6</sup> Special promise with regard to the preservation of dominant anomalous arteries holds rapidly evolving and ever more widely used EVAR technology (e.g., customized fenestrated stent grafts). Standard endoprotheses currently used for exclusion of infrarenal AAA still carry an unpredictable risk of kidney devascularisation by shutting down potentially critical accessory renal arteries.<sup>8</sup>

The approach of choice for a ruptured AAA is anterior transperitoneal,<sup>1-3</sup> whereby transection of HSK isthmus cannot always be avoided and was indeed necessary in as many as 50% of 42 collective cases identified by Stroosma et al. (double as frequent in comparison to 134 elective cases).<sup>3</sup> Bearing in mind this can lead to severe complications such as bleeding and urinary fistula, the latter also being associated with an ominous risk of aortic graft infection, an attempt at renal isthmus preservation should be made by its careful separation from the aorta and other adjustments in operative technique (e.g., isthmus retraction and posterior graft tunnelling), as seen in Fig. 2. Emergency repair for ruptured AAA is also associated with an increased hazard of anomalous renal arteries occlusion (74%, versus 51% in the elective group).<sup>3</sup>

In two largest single-centre studies of patients with HSK undergoing abdominal aortic repair (19 patients over a 31-year period described by O'Hara et al.<sup>4</sup> and 15 patients over a 20-year period in the study by Davidović et al.)<sup>2</sup> the strongest negative prognostic factor was preoperative renal failure. Because the anomalous HSK is inherently prone to various pathological conditions, chronically compromised renal function is a frequent occurrence in this clinical scenario and it adversely impacts postoperative morbidity and mortality. This is even more so true in an emergency situation, in which shock and suprarenal clamping independently contribute to a rise in serum creatinine.<sup>1-3</sup>

### Summary

The presence of HSK increases the technical complexity and risks of AAA repair, especially in an emergency setting. CTA is the preoperative diagnostic modality of choice, enabling for better reconstruction planning. Recommended surgical approach in cases of ruptured AAA is midline transperitoneal. The renal isthmus should be preserved and as many anomalous renal arteries as technically feasible revascularized to avoid the HSK-related postoperative morbidity. In elective setting, endovascular aneurysm exclusion or open repair using retroperitoneal approach are preferred treatment options.



### References

1. Frego M, Bianchera G, Angriman I, Pilon F, Fitta C, Miotto D. Abdominal aortic aneurysm with coexistent horseshoe kidney. *Surg Today* 2007;37:626-30.
2. Davidovic L, Kostic D, Jakovljevic N, Perisic M, Cinara I, Cvetkovic D, et al. Abdominal aortic surgery and horseshoe kidney. *Ann Vasc Surg.* 2004;18:725-8.
3. Stroosma OB, Kootstra G, Schurink GW. Management of aortic aneurysm in the presence of a horseshoe kidney. *Br J Surg.* 2001;88:500-9.
4. Crawford ES, Coselli JS, Safi HJ, Martin TD, Pool JL. The impact of renal fusion and ectopia on aortic surgery. *J Vasc Surg.* 1988;8:375-83.
5. Phelan JT, Bernatz PE, DeWeerd JH. Abdominal aortic aneurysm associated with a horseshoe kidney: report of a case. *Mayo Clinic Proc.* 1957;32:77-81.
6. O'Hara PJ, Hakaim AG, Hertzner NR, Krajewski LP, Cox GS, Beven EG. Surgical management of aortic aneurysm and coexistent horseshoe kidney: review of a 31-year experience. *J Vasc Surg.* 1993;17:940-7.
7. Ferko A, Krajina A, Lojik M, Zizka J, Lesko M, Eliás P, et al. [Endovascular treatment of abdominal aortic aneurysms. Morphology of aneurysms as one of the deciding indicating factors]. *Rozhl Chir.* 1997;76:589-93. Czech.
8. Brown K, Robinson D, Bray A. Customized fenestrated endovascular graft repair of abdominal aortic aneurysm with concomitant horseshoe kidney. *Vascular* 2014;22:193-7.