

# Foam sclerotherapy: the Maltese experience

Juanita Parnis, Christine Cannataci, Etimbuk Umana, Kevin Cassar

## Abstract

**Objectives:** To describe demographics and outcomes of a new sclerotherapy service – Foam sclerotherapy (FS), for venous disease at Mater Dei Hospital, Malta

**Methods:** The data of a consecutive series of patients undergoing FS were prospectively entered into a database and the results analysed. Medical notes of patients were also reviewed. Patients underwent detailed venous duplex scanning before and after each intervention and at follow-up visits.

**Results:** 121 patients underwent a total of 204 FS procedures between November 2008 and October 2011. 22% were male and 78% of the procedures were done in female patients. 151 (74%) of procedures were done in patients above the age of 50 years. 74(37%) interventions were for recurrent varicose veins and 113(55%) for chronic venous insufficiency (CEAP4-6). 77 (38%) patients had active or healed venous ulceration as the

indication for treatment. 83% of ulcers healed after foam sclerotherapy during the follow up period. 88.3% (143/162) of veins treated were completely occluded while 11.7% (19/162) were partially occluded. In the majority (64%) only one treatment session was required. One patient sustained an anaphylactic reaction to the sclerosant. No deep vein thromboses, cardiovascular events, pulmonary embolism or other major complications were reported. Skin staining was reported in 21.5% of cases.

**Conclusions:** Foam sclerotherapy is a safe and cheap treatment modality resulting in high rates of venous ulcer healing and successful venous occlusion and a very low complication rate. The success rate of foam sclerotherapy in Malta is comparable to that reported in the literature.

## Keywords

Varicose veins, sclerotherapy, varicose ulcer, ultrasonography, duplex.

## Introduction

Lower-extremity venous insufficiency is a common medical condition and occurs in about 15% of men and 35% of women.<sup>1,2,3</sup> The effect of venous insufficiency on patients' health-related quality of life (HRQOL) is substantial and comparable with other common chronic diseases such as arthritis, diabetes, and cardiovascular disease.<sup>4</sup> Foam sclerotherapy is increasingly being used for the treatment of all categories of venous disease. It involves the transformation of liquid sclerosant into a foam, by mixing the sclerosant with air or other gas, and injection of the foam into veins of the lower limb often under ultrasound control. The sclerosant induces an inflammatory response in the vein which leads to occlusion of the vein. The objective of treating incompetent veins with foam sclerotherapy is to induce thrombosis and occlusion of the veins through which reflux occurs.

The indications for treatment vary widely between uncomplicated varicose veins to venous ulceration. Venous disease of the lower limbs is extremely common, is an important cause of morbidity and consumes a significant proportion of resources of any health care system in developed countries. Treatment

**Juanita Parnis MD MRCS**  
Mater Dei Hospital, Msida, Malta  
juanita.parnis@gov.mt

**Christine Cannataci MD**  
Mater Dei Hospital, Msida, Malta  
christine.cannataci@gov.mt

**Etimbuk Umana MD**  
Mater Dei Hospital, Msida, Malta  
etimbuk.e.umana@gov.mt

**Kevin Cassar MD (Aberdeen), FRCS (Intercoll)**  
S3/S4, Department of Surgery,  
Mater Dei Hospital, Msida, Malta  
kevin.b.cassar@gov.mt

for venous disease includes traditional open surgery, endovenous laser ablation or endovenous radiofrequency ablation, amongst others. Foam sclerotherapy forms part of the clinician's armamentarium in dealing with venous disease. Foam sclerotherapy has been shown to be effective in inducing occlusion of veins treated and has been found to be as effective as traditional surgical stripping.

The major advantages of foam sclerotherapy are that it is cheap, does not require any anaesthetic and can be performed as an office procedure in a very short time. It is also acceptable to patients and can be repeated as necessary. A systematic review on foam sclerotherapy showed that serious adverse events from this type of treatment are rare.<sup>5</sup>

A foam sclerotherapy service was introduced to the Maltese health service in October 2008 after approval was obtained from the local health authorities and the sclerosant was procured. The UK National Institute of Clinical Excellence (NICE) recommends that clinicians undertaking the procedure make special arrangements for audit. The aim of this study was to report the demographics and the outcomes of this newly introduced service for treatment of venous disease at Mater Dei Hospital, Malta.

## Method

Patients referred to the vascular clinic at Mater Dei Hospital underwent a full assessment including history, examination and a complete lower limb venous duplex scan at their first visit. The venous duplex scan assessed patency and competency of deep and superficial veins of the lower limb affected. A Philips HD11 ultrasound scanner was used and all scans were performed by one experienced vascular ultrasonographer. Sites of incompetence were identified and duration of reflux measured in affected veins. Patients were offered foam sclerotherapy as a treatment option in cases of saphenofemoral incompetence, saphenopopliteal incompetence, perforator incompetence, recurrent saphenofemoral incompetence, recurrent saphenopopliteal incompetence and pelvic incompetence.

Foam sclerotherapy was performed at the one-stop vascular clinic or at the foam sclerotherapy clinic held at the Day Case Unit at Mater Dei Hospital. Depending on the source of incompetence, patients underwent venous cannulation under vision or under ultrasound control using either a 20 gauge intravenous cannula or a 25 gauge butterfly needle. Confirmation of cannulation of the vein being treated was through ultrasound visualisation of the needle or cannula as well as through satisfactory back bleeding. 1% or 3% sodium tetradecyl sulphate was used. 2mls of the sclerosant was mixed with 6mls of air using a three way tap and two 5ml Luer lock syringes using the Tessari technique. A maximum of 8mls of foam generated

in this way was used in a single session. In exceptional cases bigger volumes were used. The foam produced was then injected into the vein through the needle or cannula while the patient was requested to move the toes of the limb being treated. Correct injection of the sclerosant into the vein was confirmed by observation of a snowstorm appearance in the respective veins on ultrasound scanning. The treated leg was then bandaged using wadding, a crepe bandage and a cohesive bandage. Patients were instructed to keep the bandaging on for 24 hours and then to replace the bandages with a class II full length stocking which they were instructed to wear day and night for 5 days and then during the day for a further 2 weeks.

Patients were reviewed at the foam sclerotherapy clinic or the vascular clinic six to eight weeks after the initial treatment. Patients were asked about symptoms and complications after their treatment. A clinical examination focused on the limb to assess skin staining, paraesthesia, and ulceration. A venous duplex scan was repeated and included assessment of the deep and superficial veins in the treated leg. Based on the ultrasound scan and the clinical findings a decision was taken whether further sclerotherapy was required and if so with the patient's consent further foam sclerotherapy was performed. Occlusion of veins treated was confirmed by incompressibility on ultrasound and absence of colour flow in response to augmentation.

The details of all consecutive patients who underwent foam sclerotherapy between November 2008 and October 2011 were entered into the vascular database (Access 2000). Data was collected on patients' age, date of procedure, C part of CEAP classification, the indication for intervention, presence of chronic venous insufficiency including ulceration, the source of reflux, concentration and volume of sclerosant used, efficacy of treatment and any complications.

The medical notes of patients entered into the database were reviewed in order to identify any late complications.

## Results

One hundred and twenty one (121) patients underwent two hundred and four (204) foam sclerotherapy treatments for venous disease during the study period.

Twenty two percent (22%) (n=45) of the patients treated were males and seventy eight percent (78%) (n=159) of the procedures were done in female patients.

The age of patients treated varied between 24 and 89 years with a median age of 58 years (Figure 1). 151

procedures (74%) were done in patients above the age of 50 years.

The CEAP classification for chronic venous disorders was used to classify venous disease in this cohort. The CEAP classification below was used<sup>6</sup>:

- C0: No visible or palpable signs of venous disease
- C1: Telangectasies or reticular veins
- C2: Varicose veins; distinguished from reticular veins by a diameter of 3mm or more.
- C3: Oedema.
- C4: Changes in skin and subcutaneous tissue secondary to CVD, now divided in 2 subclasses to better define the differing severity of venous disease.
- C4a: Pigmentation or eczema.
- C4b: Lipodermatosclerosis or atrophie blanche.
- C5: Healed venous ulcer.
- C6: Active venous ulcer.

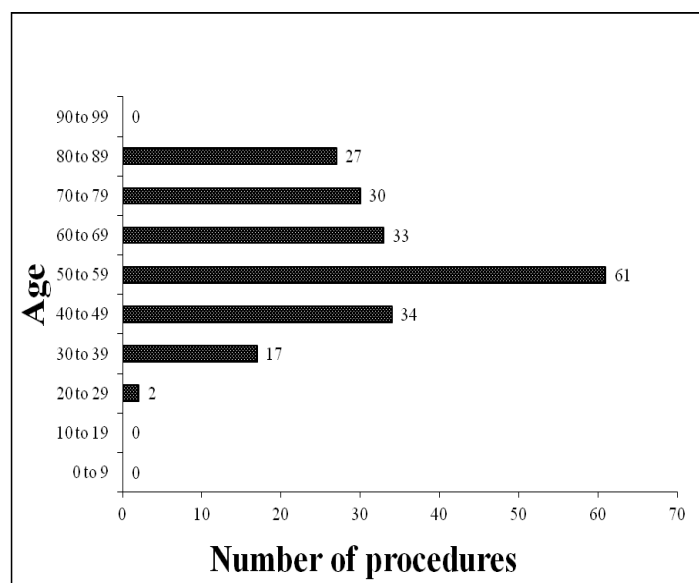


Figure 1: Number of procedures performed in each age group

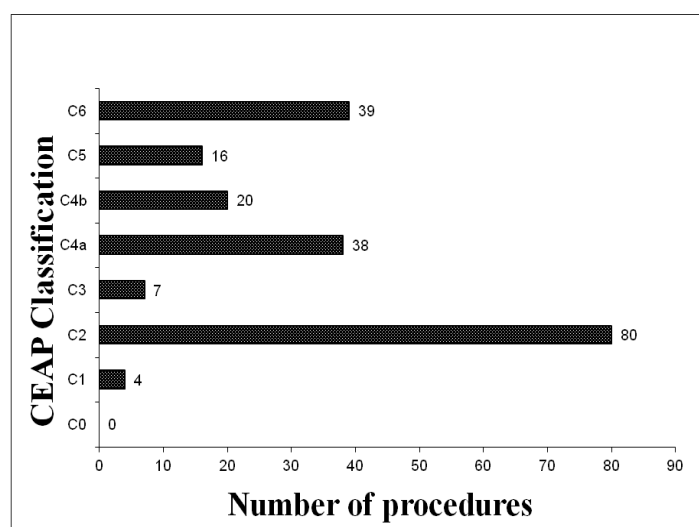


Figure 2: Number of patients undergoing foam sclerotherapy in each CEAP group

Four (1.96%) procedures were done for C1 disease, 80 (39.22%) procedures were done for C2 disease, 7 (3.43%) procedures for C3 disease, 38 (18.63%) procedures for C4a disease, 20 (9.80%) procedures for C4b disease, 16 (7.84%) procedures for C5 disease and 39 (19.12%) procedures for C6 disease (Figure 2). Twenty one percent (n=42) of the procedures were done in patients with active ulceration and 35 (29%) patients had healed ulcers at the time of treatment.

Sixty three percent (n=129) of procedures were done for primary venous disease and 37% (n=75) of procedures were treated for recurrent varicose veins. The source of incompetence was the saphenofemoral junction in 117 (57.35%) procedures, at the saphenopopliteal junction in 11 (5.39%) procedures, perforator incompetence in 23 (11.27%) procedures, pelvic incompetence in 44 (21.57%) procedures and 26 (12.75%) of the procedures, the incompetence was at other anatomical locations (Figure 3). Some patients had more than one source of incompetence.

In 121 procedures (60%) 1% STD and in 80 procedures (39%) 3% STD was used. In the remaining 3 procedures (1%), the concentration used was not documented.

The volume of sclerosant used varied between procedures. In 2 of the procedures (1%), 4ml of sclerosant was used, in 6 procedures (3%) 6ml of sclerosant was used, in 167 procedures (82%) 8ml of sclerosant was used, in 1 procedure (<1%) 16ml of sclerosant was used and in 28 procedures (14%) the amount of sclerosant used was not recorded.

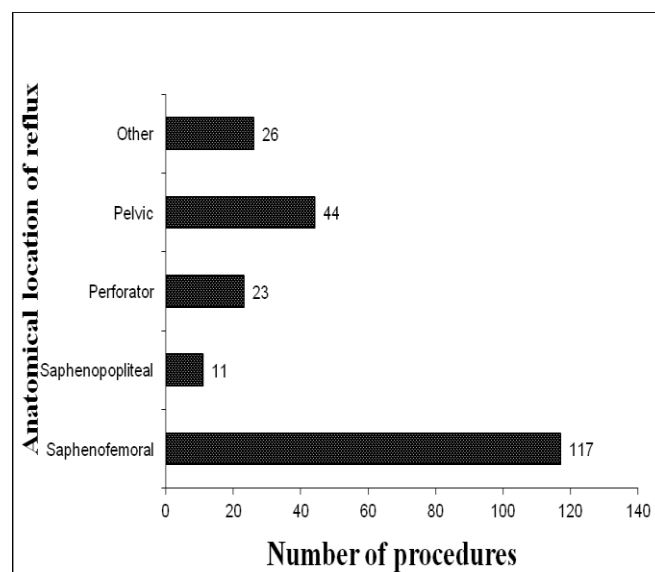
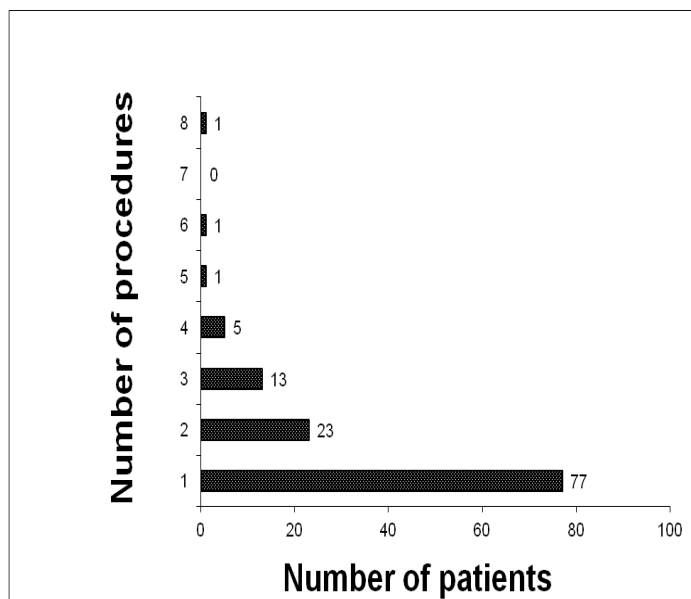


Figure 3: Anatomical site of venous incompetence



**Figure 4:** Number of procedures done on the same patient

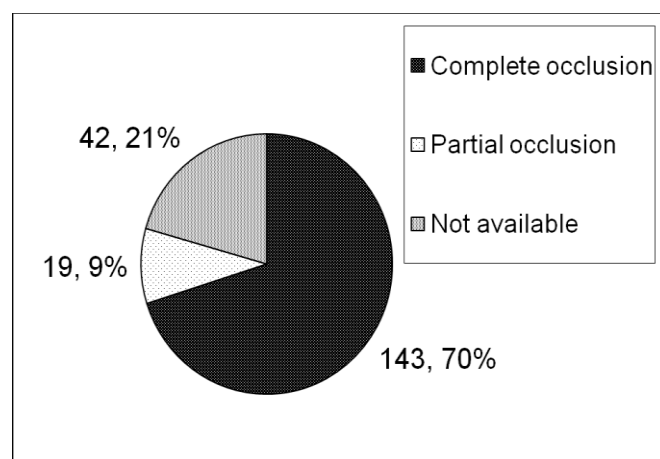
Fifty seven percent ( $n=117$ ) of the procedures were done on the left lower limb. Forty six percent ( $n=93$ ) of the procedures were bilateral and 54% ( $n=111$ ) of the procedures were unilateral.

Seventy seven (63.63%) patients had one single treatment session, 23 (19.01%) patients had 2 treatments, 13 (10.74%) patients had 3 treatments, 5 (4.13%) patients had 4 treatments, 1 (0.83%) patient had 5 treatments, 1 (0.83%) patient had 6 treatments, and 1 (0.83%) patient had 8 treatments (Figure 4).

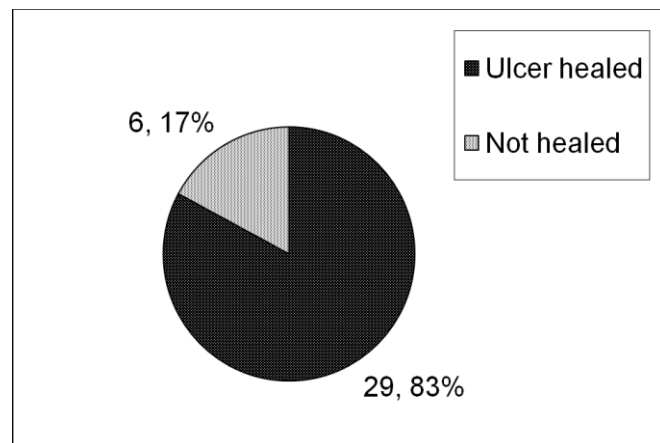
Complete occlusion of the veins injected with sclerosant occurred in 70% of procedures ( $n=143$ ), partial occlusion occurred in 9% of procedures ( $n=19$ ) and in the remaining 21% of procedures ( $n=42$ ) this data was not recorded (Figure 5). Amongst patients with complete records 88.3% (143/162) of veins treated were completely occluded while 11.7% (19/162) were only partially occluded. Amongst patients with active ulceration 83% ( $n=29$ ) healed their ulcer after foam sclerotherapy. In the remaining 17% ( $n=6$ ) of patients, the ulcer had still not healed at the end of follow up (Median follow up period 11 months) (Figure 6).

No cases of fits, transient visual disturbances, pulmonary embolism, deep vein thrombosis, myocardial infarction or cerebrovascular accidents were recorded. One patient (0.49%) suffered anaphylaxis soon after injection of sclerosant for which she was treated and made a full recovery. One patient complained of pruritus which was short lived lasting a few minutes and which resolved spontaneously.

No haematomata or cutaneous ulceration occurred. Forty four patients (21.57%) developed skin pigmentation and in 1 case (0.49%), the patient experienced paraesthesia at the site of injection.



**Figure 5:** Number of patients and percentages with partial or complete occlusion of the treated veins



**Figure 6:** Number of patients and percentages with healed or unhealed ulcers after foam sclerotherapy

## Discussion

The results reported in this paper indicate that ultrasound guided foam sclerotherapy is a useful treatment option for venous disease of the lower limb and which can be performed safely and with minimal complications. The vein occlusion rate for this cohort was over 88% of patients which is comparable to the results reported in other series<sup>(7)</sup> estimated at over 80% at 3 months. Even more rewarding was the very high ulcer healing rate in those treated for active ulceration (83%). A considerable proportion of patients required only one treatment session.

The complication rate reported in our series is very low and it is recognised that in the vast majority of patients with skin staining, which was the most common complication, this will resolve with time and it is only a very small proportion of patients (1%) who will have permanent skin staining.

The major advantages of foam sclerotherapy include the fact that it is a relatively cheap form of

treatment, can be done in a short time and can be done in an office setting without the requirement for anaesthetic or any specialised equipment or tools apart from the ultrasound scanner. In the context of increasing demand on hospital beds, another considerable advantage is that foam sclerotherapy is performed on an out patient basis and compared to traditional surgery which requires at least day case admission, foam sclerotherapy does not take up any hospital beds at all.

There is mounting evidence for the efficacy of foam sclerotherapy at least in the short term. As this is a relatively new treatment modality the long term results are still being investigated. However, even if recurrence rates or recanalisation rates turn out to be high in the long term, retreatment with sclerotherapy is still possible without any increase in morbidity. There are ongoing randomised trials comparing the efficacy of traditional surgery, endovenous laser ablation and foam sclerotherapy which will yield more information as to the relative efficacy of foam sclerotherapy. The CLaSS trial is an ongoing multicentre randomised controlled trial comparing foam sclerotherapy alone, or in combination with endovenous laser treatment, with conventional surgery as treatment for varicose veins. This trial will be comparing clinical and cost effectiveness of the different treatment modalities and is due to report in 2014. A recent meta-analysis however concluded that foam sclerotherapy is at least as effective as surgical stripping in the treatment of lower limb varicosities.<sup>(7)</sup>

Foam sclerotherapy is particularly useful in the treatment of recurrent varicose veins after surgical treatment. Redo surgery for recurrent disease particularly in the groin as well as in the popliteal fossa is associated with significant morbidity, poor clinical outcomes and high rates of re-recurrence. In this context the advantage of foam sclerotherapy is that no further surgery is required and the fact that the foam can be guided into small and tortuous veins which are not accessible to surgical treatment. The other major advantage of foam

sclerotherapy is that this can be used in frail and elderly patients who are poor surgical candidates.

In conclusion, this paper adds further evidence that foam sclerotherapy is a safe and effective treatment modality for lower limb venous disease. It demonstrates that results obtained with foam sclerotherapy in Malta are similar to those reported in the literature. It also confirms that high venous occlusion rates and ulcer healing rates can be achieved with foam sclerotherapy as the sole treatment modality for venous disease secondary to various sources of incompetence.

### Acknowledgements

We would like to thank Ms Abigail Sultana for her IT assistance and Ms Maria Persico for her secretarial support.

### References

1. Callam MJ. Epidemiology of varicose veins. *Br J Surg* 1994;81:167-73.
2. Evans CJ, Fowkes FGR, Ruckley CV, Lee AJ. Prevalence of varicose veins and chronic venous insufficiency in men and women in the general population: Edinburgh Vein Study. *J Epidemiol Community Health* 1999;53:149-53.
3. Margolis DJ, Bilker W, Santanna J, Baumgarten M. Venous leg ulcer: incidence and prevalence in the elderly. *J Am Acad Dermatol* 2002;46:381-6.
4. Andreozzi GM, Cordova RM, Scomparin A, Martini R, D'Eri A, Andreozzi F; Quality of Life Working Group on Vascular Medicine of SIAPAV. Quality of life in chronic venous insufficiency. An Italian pilot study of the Triveneto Region. *Int Angiol* 2005;24:272-7.
5. Jia X, Mowatt G, Burr J.M, Cassar K, Cook J, Fraser C. Systematic review of foam sclerotherapy for varicose veins. *British Journal of Surgery*. 2007 Aug 94 (8): 925-936.
6. Eklöf B, Rutherford RB, Bergan JJ, Carpentier PH, Gloviczki P, Kistner RL et al; American Venous Forum International Ad Hoc Committee for Revision of the CEAP Classification. *Journal of Vascular Surgery*. 2004 Dec;40(6):1248-52.
7. Van den Bos R, Arends L, Kockaert M, Neumann M, Nijsten T. Endovenous therapies of lower extremity varicosities; A meta-analysis. *J Vasc Surg* 2009; 49:230-9.