

# CLINICAL ASPECTS OF MEDIASTINAL EMPHYSEMA (PNEUMOMEDIASTINUM)

LUIS VASSALLO

B.Sc., M.D., M.R.C.P. (LOND.), M.R.C.P. (EDIN.),  
M.R.C.P. (GLASG.)

*Department of Medicine,  
St. Luke's Hospital  
and Royal University of Malta.*

**Summary:** The etiology of spontaneous mediastinal emphysema is varied. Two illustrative cases are described — one related to bronchial asthma, and the other to scuba diving. The characteristic clinical findings, including subcutaneous emphysema and the abnormal auscultatory signs are discussed. The differential diagnosis, including the close resemblance of mediastinal emphysema to a left medial pneumothorax is considered. The diagnostic importance of a left lateral chest X-ray taken in expiration is stressed. Management should be conservative unless clinical deterioration continues.

## Etiology

The uncommon syndrome of mediastinal emphysema (pneumomediastinum) was recognised as long ago as 1819 when Laennec described it as interlobular emphysema stating that "when extravasation exists near the root of the lungs, it speedily extends to the mediastinum, and from there crosses to the neck and over the whole subcutaneous and intermuscular substance of the body". This highly characteristic clinical tendency to manifest itself by subcutaneous emphysema in the neck was found by Bodey (1961) to be present in 87% of the cases he analysed. Numerous causes are to be found in the literature and include such varied ones as influenzal pneumonia, (Clark and Synnot, 1919), smallpox, (Wilkinson, 1943), whooping cough, (Worden and Vardy, 1939), and measles, (Block and Vardy, 1968) among the infective causes. It can occur in the days old infant (Han, Rudolph and Teng, 1963) or may complicate labour

(Philips, 1938). One of the most common causes is bronchial asthma (McGovern *et al.*, 1961), and the condition is well recognized as occasionally complicating tracheotomy (Bergstrom and Diamant, 1960). Mediastinal emphysema may also be the presenting sign of tracheal neoplasia (Darch, 1962), and may rarely follow an infradiaphragmatic condition such as rupture of a gastric ulcer (Welty, 1949). An increasingly important cause of the syndrome is skin diving and scuba (self-contained under water breathing apparatus) diving.

The first case presented in this paper was related to scuba diving and illustrated the dangers of this sport while the second case was associated with bronchial asthma.

## Case Reports

### Case No. 1

An apparently healthy 32 year old American tourist had come to Malta for a short vacation and had gone scuba diving with hired apparatus. This had been his first experience of scuba diving. He had remained scuba diving for about an hour feeling perfectly well. After surfacing from one of his dives, he noted pain over the front of his chest and felt his face becoming bloated. He started having difficulty in keeping his eyelids open because of swelling of his eyelids. He landed on shore breathless, with one eye completely closed and the other half open. He was immediately rushed to hospital by bystanders.

On admission, he was mildly breathless with a pulse of 96 per minute and a B.P. of 120/70 mm. Hg. Crackling sub-

cutaneous emphysema could be elicited over his face and neck and over the chest wall. Auscultation of the heart revealed a characteristic crunching sound in systole. This sound was still present when he was asked to hold his breath. His right eye was completely closed because of the subcutaneous emphysema.

There was no relevant past medical history. In particular, he denied any recent or old respiratory illnesses. He was a moderate cigarette smoker.

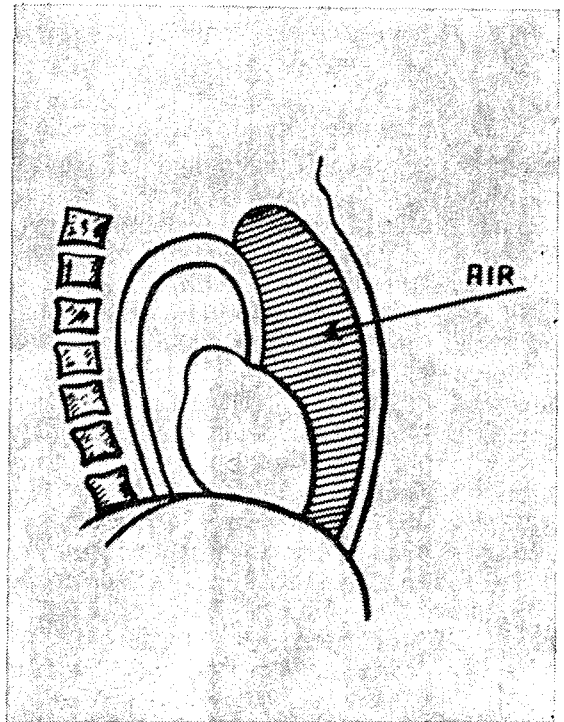
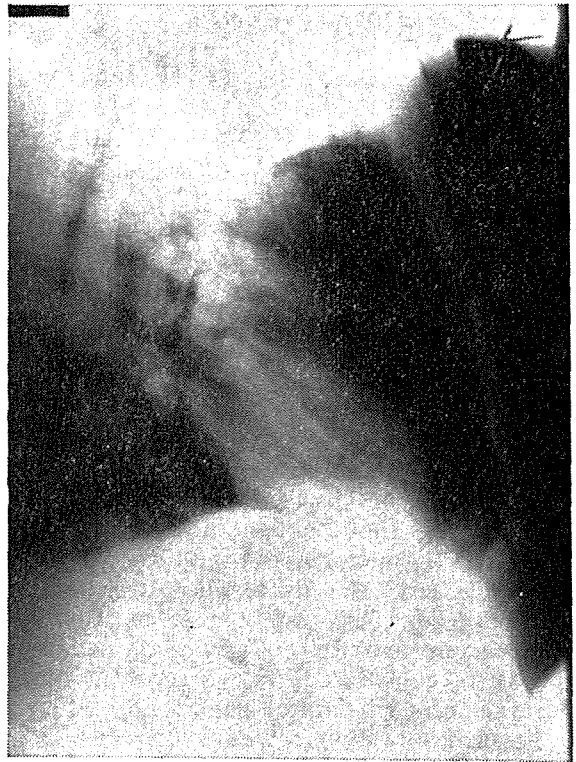He was kept propped up in bed and was made to inhale oxygen (95%). His general condition quickly improved and within a few hours most of the subcutaneous emphysema had been absorbed. There was no trace of subcutaneous air after one week. He was then symptom free. Radiological studies made on admission showed the characteristic features of mediastinal emphysema.

The patient was discharged from hospital after ten days.

### Case No. 2

A thirty year old Maltese male was admitted to hospital as an emergency on 1. 1. 68 because of the sudden worsening of his status asthmaticus. He had suffered from frequent attacks of asthma since he was a child, and was accustomed to using an inhaler spray with good effect to abort his asthmatic attacks. On the morning of admission an asthmatic attack had started. As he had run out of inhaler spray he was unable to abort the attack in the usual way as the nearby chemist's shop was closed because of the New Year holiday. A few hours after the onset of his symptoms he had noted sudden increase in the tight feeling across his chest and his breathlessness had increased. His relatives observed increasing cyanosis and swelling of the neck and face. His appearance became alarming and he was therefore taken to hospital.

On admission, his respiratory rate was 40 per minute, his B.P. was 140/90 mm. Hg. and his pulse was regular at 120 beats per minute. He was moderately cyanosed and on palpation of the swelling



Displacement of the heart posteriorly by air in anterior mediastinum.

of his neck, subcutaneous emphysema was diagnosed. There was a crunching sound on auscultation at the cardiac apex. He was orthopnoeic. There were no other abnormal features on examination apart from complete obliteration of cardiac dullness and the usual wheezing typical of asthma.

He was given oxygen to breathe, in as high a concentration as possible. He was started on Aminophylline intramuscular injections and Choledyl tablets 200 mgms. t.d.s. were prescribed. He was also sedated.

He felt better within the hour and on re-examination two hours later, the crunching sound had disappeared. On the fifth day there was no clinical evidence of subcutaneous emphysema.

Radiological studies taken within half an hour of admission were typical of mediastinal emphysema, the left lateral chest X-ray showing marked displacement of the cardiac outline posteriorly. *Fig. 1.*

The patient was discharged from hospital after a fortnight. A chest X-ray at the time of discharge showed no abnormality.

### Discussion

These two cases illustrate two widely different etiologies of the syndrome. The second patient with bronchial asthma is typical of the commonest cause of mediastinal emphysema, though it usually occurs far more frequently in asthmatic children than in adults. Schwartz (1945) had collected 25 cases associated with bronchial asthma, from the literature. Severe air-trapping and bronchospasm cause rupture of the alveolar walls and air is allowed to dissect along the perivascular and peribronchial interstitial tissue into the mediastinum. Air enters the interstitial tissue during inspiration and is then slowly squeezed towards the mediastinum during expiration.

In both cases three classical signs associated with pneumomediastinum were elicited. The first and least important was

the obliteration of cardiac dullness by the air trapped in front of the mediastinum. This sign is not in any way pathognomonic, as it can be similarly produced by a pneumothorax.

The second sign, consisting of the "crunching" crepitations synchronous with the heart beats, is especially characteristic, though again not pathognomonic. It is believed to have been first described by Muller in 1888, but it was left to Hamman (1939) to re-emphasise its significance. He put spontaneous mediastinal emphysema on the medical map by analysing its incidence among the in-patient admissions over many years to the Johns Hopkins Hospital. The sign has become popularly known as Hamman's sign or crunch. It is worth stressing that this sign is not present in every case of pneumomediastinum. Bodey (1961), for instance found that it was only present in 53% of cases analysed by him. He had continued Hamman's study and calculated that the incidence of pneumomediastinum out of 654,612 admissions was about 1 in 40,000.

The crunch is usually best heard along the left sternal edge but not uncommonly it may be quite well heard at the apex, xiphoid area and occasionally over the entire chest wall. Very rarely the sound may be heard by an observer some distance away from the patient. The sound which may be heard in either systole or diastole is almost always accentuated in systole. It is amusing, on reviewing the literature associated with the description of the sound, to read of the various imaginative words or phrases used to describe it. Apart from its "crunching" quality, it has been thought of as "bubbling" or "tapping". It has been likened to "crackling of dry cellophane" or "the crunching sound of footsteps on dry packed snow on a brisk winter night" (Sulavik, 1962). Other descriptions used have included "click", "knock", "the sound of pebbles falling on taut canvas", "peas dropping on to the bottom of a pan", "leatherv", etc. (Cimmino, 1966). Patients' descriptions, keeping up with their medical masters, are likewise varied! The patient may feel as "if water and air are being

mixed together with each heart beat", or that there is a "wet sponge" in the chest (Sulavik, 1962).

The sounds may be transient and last only a few hours or else may persist for several weeks. The mechanism of production is probably due to the beating action of the heart on the numerous small air bubbles trapped between the heart and the anterior chest wall.

In their differential diagnosis, other conditions that must be considered include a left-sided medial pneumothorax (most important), bullous emphysema of the lingular segments, and dilatation of the oesophagus. An erroneous diagnosis of pericarditis may be made if the sounds are faint (Koshy, 1961).

The third clinical sign that is most helpful in the differential diagnosis is that of subcutaneous emphysema in the tissues of the neck, face or chest wall. It should be emphasised that the detection of subcutaneous emphysema without any apparent surgical cause should make the observer diagnose pneumomediastinum, as the air dissecting the fascial planes to cause supraclavicular, cervical or facial swelling must have originated there.

In both patients described in this paper early and adequate radiological studies were made. Anteroposterior and lateral chest X-ray were taken with a portable machine within the hour of admission. Surprisingly few patients reported in the literature have had a lateral chest X-ray taken. The view is the best one as it shows the amount of air in the mediastinum and the degree of shift posteriorly of the cardiac outline. The view should be taken in full expiration. In both patients, very definite evidence of posterior mediastinal shift was obtained. Repeat views days later showed disappearance of the shift with "reapposition" of the heart in the lateral view against the posterior wall of the sternum.

Review of the literature on mediastinal emphysema and analysis of the cases reported shows considerable diagnostic confusion between the condition and a left pneumothorax. Chapman in 1955

found a left pneumothorax in almost 50% of 47 cases studied. It was only too often that a diagnosis of mediastinal emphysema was made on insufficient evidence. Scott (1957) noted that an X-ray to show pneumomediastinum was carried out in only 41 out of 98 cases analysed. Hamman's crunch was however recorded in 90 of those patients. That the evidence on which these 41 cases are based is shaky is clear from the fact that at least 17 of these cases had a left pneumothorax.

Again during the last few years, emphasis has been placed on the lack of pathognomoncity of Hamman's crunch. Semple and Lancaster (1961) feel that the sign is far from pathognomonic and that it is more commonly present in a left pneumothorax than in mediastinal emphysema and that a left pneumothorax should be the foremost diagnosis to be considered whenever a "crunch" is heard.

Lastly, as far as differential diagnosis is concerned, the remote possibility of an underlying myocardial infarction should be borne in mind especially in the older age groups. It must not be forgotten that the commonest symptom complained of is chest pain, and that at least two instances have been recorded where mediastinal emphysema was precipitated by attacks of left ventricular failure following coronary thrombosis (Nash, 1957; Danish, 1954).

Several lines of treatment have been advocated by different authors. The first principle of treatment is management of the factor precipitating mediastinal emphysema — if a cause can be demonstrated. Thus in status asthmaticus vigorous treatment of the underlying bronchial asthma should be instituted. If the pneumomediastinum is the result of decompression sickness, then recompression in the more severe cases should be carried out.

The simplest and probably most efficacious line of treatment is the breathing of oxygen by mask — preferably 95% oxygen. Both patients here were treated with oxygen. Relief resulted within a short time. Breathing oxygen should be combined with rest and sedation.

Pneumomediastinum, when severe, is a potentially fatal condition. Progressively more heroic measures may be needed, depending on the degree of severity as judged by the cardiorespiratory embarrassment present. One of the simpler methods that may be tried is the needle aspiration of air. Some authors suggest cervical mediastinotomy, while as an extreme measure, tracheotomy has had to be carried out as lifesaving procedure. This seems prima facie paradoxical when one considers that one of the causes of mediastinal emphysema is tracheotomy (Bergstrom and Diamant, 1960). One must always remember the possibility of an associated pneumothorax, as the treatment that may have to be instituted is the introduction of an intercostal needle. In severe cases secondary to decompression illness, the treatment of choice is the use of a recompression chamber as was first carried out by Schulte (1957).

Whatever the cause of the mediastinal emphysema, the management should be conservative unless there are signs of imminent danger to life or evidence of deterioration in the general condition.

### References

- BERGSTROM, O., and DIAMANT, H. (1960). *A.M.A. Arch. Otolaryng.*, 71, 628.
- BLOCK, A., and VARDY, P. (1968). *Clin. Pediat.*, 7, 7.
- BODEY, G.P. (1961). *Ann. Intern. Med.*, 54, 46.
- CHAPMAN, J.S. (1955). *Amer. J. Med.*, 18, 547.
- CIMMINO, C.V. (1966). *Virg. med. Monthly*, 93, 106.
- CLARK, E., and SYNOTT, M.J. (1919). *Amer. J. Med. Sci.*, 157, 219.
- DANISH, M. (1954). *New Eng. J. Med.*, 250, 677.
- DARCH, G.H. (1968). *Brit. J. Dis. Chest*, 56, 212.
- HAMMAN, L. (1939). *Bull. Johns Hopk. Hosp.*, 64, 1.
- HAN, S.Y., RUDOLPH, A.J., and TENG, G.T. (1963). *J. Pediat.*, 62, 754.
- KOSHY, T.S., ANKLESARIA, X.J., and CHERIAN, G. (1961). *J. Ind. med. Ass.*, 36, 381.
- LAENNEC, R.T.H. (1827). *Treatise on Diseases of the Chest and on medical auscultation*. Trans. by J. FORBES, T. & G. Underwood. London.
- McGOVERN, J.P., SINGLETON, E.B., OZKARAGOZ, M., HENSEL, A.E., JR., and JOHNSTON, T.G. (1961). *Ann. Allerg.*, 19, 1139.
- MULLER, H. Quoted by SULAVIK.
- NASH, J.C. (1957). *Ann. Intern. Med.*, 46, 595.
- PHILLIPS, P. (1938). *Brit. Med. J.*, 1, 54.
- SCHULTE, J.H. (1957). *U.S. Armed Forces med. J.*, 8, 469.
- SCOTT, J.T. (1957). *Dis. Chest*, 32, 421.
- SCHWARTZ, E. (1945). *J. Allerg.*, 16, 279.
- SEMPLE, T., and LANCASTER, W.W. (1961). *Brit. med. J.*, 1, 1342.
- SULAVIK, S. (1962). *Gen. Practit.*, 26, 104.
- WELTY, D.M. (1949). *Ann. Intern. Med.*, 30, 205.
- WILKINSON, P. (1943). *Brit. med. J.*, 2, 56.
- WORDEN, E.M., and CHAISSON, A.F. (1939). *Canad. med. Ass. J.*, 41, 237.