

Familial angiosarcoma of the heart

Aaron R. Casha, FRCS,^a Leslie A. Davidson, MRCPATH,^b P. Roberts, Dip RCPATH,^c and R. Unnikrishnan Nair, FRCS,^a
Leeds, United Kingdom

Primarily cardiac tumors are rare¹ and about 75% are benign, of which 75% are atrial myxomas.² Angiosarcomas are the most common malignant primary cardiac tumors, with 90% arising in the left atrium and 10% in the right atrium.³ This is the first report of a primary cardiac tumor, an angiosarcoma, with a familial incidence.

Clinical Summaries

CASE 1. A previously healthy 24-year-old woman sought treatment with chest pain, exertional dyspnea, and episodic dizziness. A transthoracic echocardiogram revealed an 8.9 × 8.4-cm right atrial mass, which was confirmed by computed tomography and magnetic resonance imaging. This proved to be angiosarcoma (Figure 1). There were no distant metastases. Surgery was aimed at debulking the tumor to alleviate obstructive symptoms. At operation, the right atrial free wall was excised and reconstructed with a bovine pericardial patch (Baxter Healthcare Corporation CardioVascular Group, Irvine, Calif), and the right ventricle was debulked. Adjuvant chemotherapy was given. Four months after the operation the patient was well, but at 6 months pulmonary metastases developed. The patient died 9 months after the operation.

CASE 2. A previously healthy 31-year-old man, the father of the patient in case 1, sought treatment in 1985 with shortness of breath, vague central discomfort, and anemia. Echocardiography showed a mass in the pericardial cavity and an echodense effusion. Computed tomographic scan showed multiple secondary deposits in both lungs, right pleural effusion, and a mass located anteriorly in the heart. Because of increasing dyspnea and possible tamponade, pericardial drainage was attempted. This resulted in perforation of the right ventricle, which was repaired with mattress sutures. The patient underwent adjuvant chemotherapy but died approximately 3 months after the operation with bilateral multiple pulmonary metastases.

The cardiac tumors in cases 1 and 2 were histologically similar, composed of pleomorphic spindle-shaped and epithelioid cells with high nuclear cytoplasmic ratios and eosinophilic cytoplasm (Figure 2). In places these cells lined anastomosing vascular spaces. Both tumors were immunopositive for endothelial antigens CD31 and CD34. These features indicate that both tumors were angiosarcomas.

Cytogenetic studies were performed on tissue samples from case 1. Tumor tissue was received within 24 hours of resection, and cell suspensions were obtained by mechanical and trypsin-collagenase enzymatic treatment.⁴ Culture was established in flasks containing a 50:50 mixture of Ham F10 medium buffered with N-2-hydroxyethylpiperazine-N-2-ethanesulfonic acid and Roswell Park Memorial Institute medium buffered with bicarbonate, supplemented with 10% fetal calf serum, along with antibiotics and glutamine. Cells were grown in an open system for 6 days and harvested according to standard techniques. Slides were analyzed by Giemsa/Trypsin/Leishman banding. Although there was some variation from cell to cell, consistent clonal chromosome changes are described in the following composite karyotype (Figure 3): 50-51, XX,+1[5],der(1;13)(q10;q10)[3],+2[5],+7[5],+8[5], add(8)(p2?)×2[6], + add(8)(p23)[2], +18[3],-19[4],+22[4][cp6].

The abnormalities are mainly numeric, with gains of chromosomes 1, 2, 7, 8, and 22 and monosomy 19. The most noteworthy abnormality was the presence in all cells of two copies of an unbalanced rearrangement of 8p, producing loss of distal 8p.

From the Departments of Cardiothoracic Surgery^a and Histopathology,^b Leeds General Infirmary, and the Cytogenetics Unit,^c St James Hospital, Leeds, United Kingdom.

Received for publication June 8, 2001; accepted for publication Aug 11, 2001.

Address for reprints: R. Unnikrishnan Nair, FRCS, Department of Cardiothoracic Surgery, Leeds General Infirmary, Leeds LS1 3EX, United Kingdom.

J Thorac Cardiovasc Surg 2002;124:392-4

Copyright © 2002 by The American Association for Thoracic Surgery

0022-5223/2002 \$35.00+0 12/54/122314

doi:10.1067/mtc.2002.122314




Figure 1. Right atrial cardiac angiosarcoma.

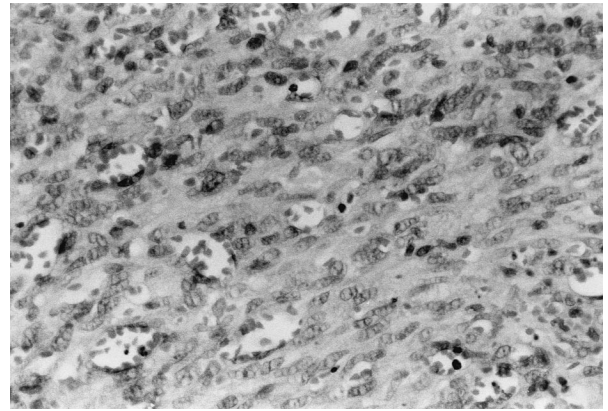


Figure 2. Cardiac angiosarcoma from case 2 (father), showing small blood vessels lined by neoplastic endothelial cells in stroma of malignant spindle-shaped endothelial cells.

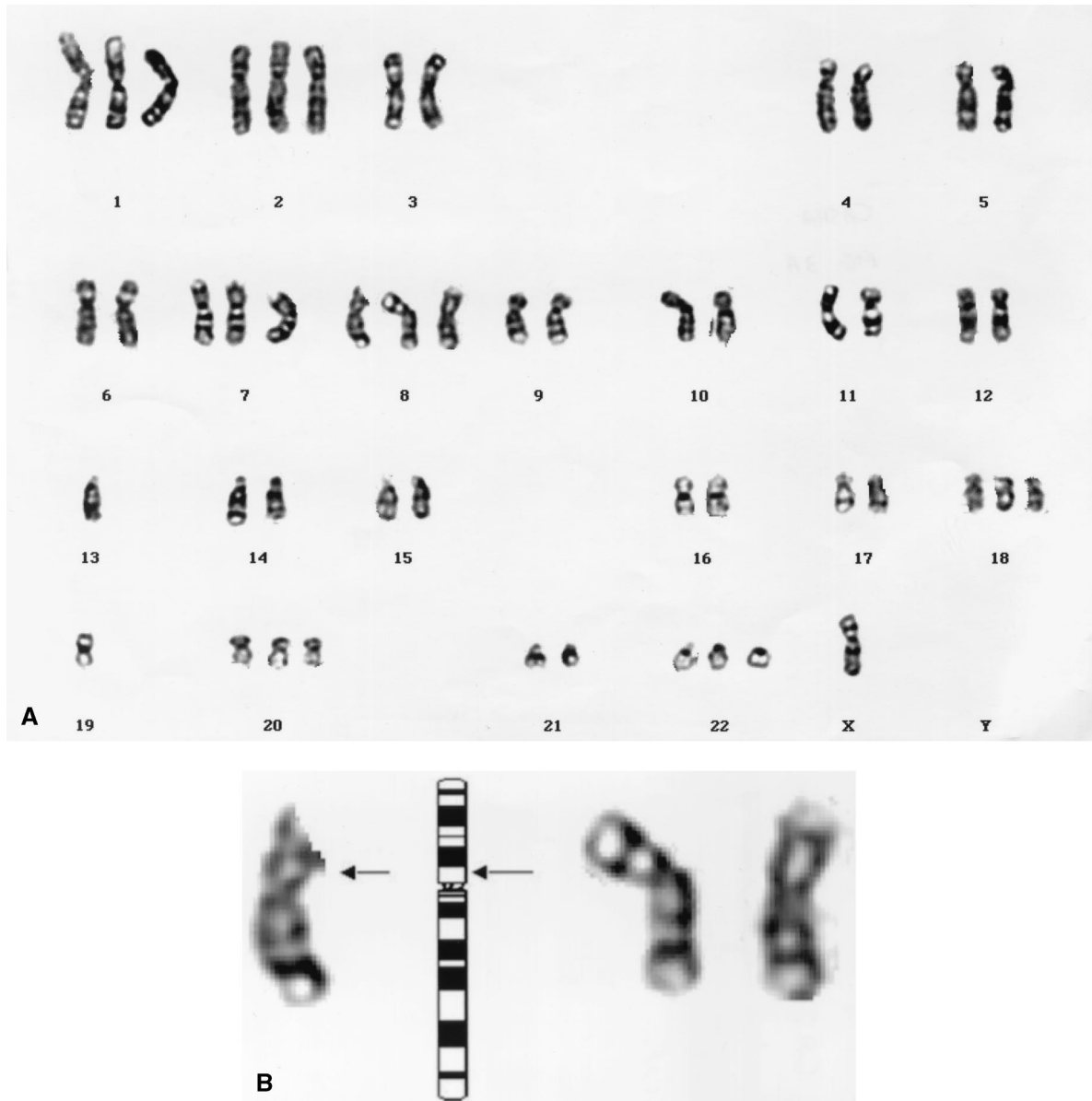


Figure 3. A, Representative karyotype of case 1 (daughter) showing all chromosome changes. There is an unbalanced whole-arm der(1;13) translocation giving rise to relative 1p loss, and two copies of unbalanced rearrangement of 8p, producing loss of distal 8p. Some cells also contained rearrangement of 8p23 in third chromosome 8. Full composite karyotype formula is shown in the text. B, Partial karyotype of case 1 (daughter) showing normal chromosome 8 and two copies of add(8p) abnormality. Arrows on normal 8 and on idiogram indicate probable site of break.

Comment

Primary tumors have been recognized as rare cardiac diseases since Columbus of Padua's description in 1559. The first antemortem diagnosis was recorded in 1934. The introduction of echocardiography in 1968 revolutionized the diagnosis of these tumors, allowing their preoperative localization. Magnetic resonance imaging can define the extent of invasion and may allow histogenetic classification.

Most malignant cardiac tumors are sarcomas.⁵ Angiosarcomas are the most common sarcomas,³ accounting for 26% to 37%. They commonly occur in the right atrium, as do other malignant tumors. Right atrial tumors, as in our case 1, are more likely to be malignant than are left atrial tumors.⁶ As many as half of all right atrial tumors are malignant. Twice as many men as women are affected, in the opposite ratio to atrial myxomas.

There is little cytogenetic documentation of angiosarcomas,⁷ and at present no specific abnormalities are recognized. Our case 1 demonstrated a hyperdiploid karyotype with trisomy of chromosomes 1, 2, 7, 8, 18, and 22 and monosomy of chromosome 19. Of particular interest was the presence of two copies (occasionally three) of an unbalanced rearrangement of 8p. This appears to have resulted in the loss of 8p2 to 8pter, a region frequently deleted in solid tumors. Such homozygous loss suggests the possible involvement of a tumor suppressor gene in this region. A number of candidate genes on 8p have been described in other tumor types. These include *DLC1*, a suggested candidate tumor suppressor gene at 8p22-8p21.3 implicated in liver, prostate, lung, colorectal, and breast cancers⁸; *N33*, a gene within a homozygous 8p22 deletion seen in prostate cancer⁹; and *PDGRL* at 8p22-8p21.3, which is involved in hepatocellular cancer.¹⁰ We therefore recommend further investigation of 8p in angiosarcomas, with particular regard to any possible loss of heterozygosity, to establish whether this region plays a role in the pathogenesis of this tumor type.

Cardiac angiosarcomas usually have symptoms caused by four pathophysiologic mechanisms but may also be found incidentally. Obstruction of intracardiac blood flow or valves and caval obstruction can also occur. Local invasion may lead to arrhythmias, pericardial effusion or tamponade, and sudden death from arrhythmias or embolization. Eighty percent of patients have systemic metastasis at the time of diagnosis. The most common presentation is congestive heart failure (75%), followed by embolism, tachyarrhythmia, and chest pain.² Our patients had three of these features. Cardiac tumors may cause systemic or constitutional symptoms, such as malaise and fever.

Wide surgical excision remains the cornerstone of surgical management of cardiac tumors. It may be difficult to obtain tumor-

free margins because of local spread or distant metastases. Complete resection is possible in as many as a third of cases.⁶ A few patients with cardiac sarcomas have received transplants, although the role of cardiac transplantation remains unclear.^{11,12} If resection is incomplete, the tumor may recur even after chemotherapy and the patient may die of metastatic disease. The long-term results are poor, with an overall survival of less than 1 year. With unresectable sarcomas, radiation and chemotherapy with adriamycin give a limited response.

This report describes a cardiac hemangiosarcoma in a 24-year-old woman whose father had died at the age of 31 years of a histologically and immunochemically identical tumor. We believe that this is the first reported description in the literature of familial angiosarcoma of the heart.

References

- Burke AP, Cowan D, Virmani R. Primary sarcomas of the heart. *Cancer*. 1992;69:387-95.
- Vander Salm TJ. Unusual primary tumors of the heart. *Semin Thorac Cardiovasc Surg*. 2000;12:89-100.
- Burke A, Virmani R. The atlas of tumor pathology - tumors of the heart and great vessels. 3rd series, fascicle 16. Washington, DC: Armed Forces Institute of Pathology; 1996. p. 127-70.
- Limon J, Dal Cin P, Sandberg AA. Application of long term collagenase disaggregation for the cytogenetic analysis of human solid tumors. *Cancer Genet Cytogenet*. 1986;23:305-13.
- Molina JE, Edwards JE, Ward HB. Primary cardiac tumors: experience at the University of Minnesota. *Thorac Cardiovasc Surg*. 1990;38 Suppl 2:183-91.
- Perchinsky MJ, Lichtenstein SV, Tyers GF. Primary cardiac tumors: forty years' experience with 71 patients. *Cancer*. 1997;79:1809-15.
- Schuborg C, Mertens F, Rydholm A, Brosjo O, Dictor M, Mitelman F, et al. Cytogenetic analysis of four angiosarcomas from deep and superficial soft tissue. *Cancer Genet Cytogenet*. 1998;100:52-6.
- Yuan BZ, Miller MJ, Keck CL, Zimonjic DB, Thorgeirsson SS, Popescu NC. Cloning, characterisation and chromosomal localisation of a gene frequently deleted in human liver cancer (*DLC-1*) homologous to rat *RhoGAP*. *Cancer Res*. 1998;58:2196-9.
- Bova OS, MacGrogan D, Levy A, Pin S, Bookstein R, Isaacs WB. Physical mapping of chromosome 8p22 markers and their homozygous deletion in a metastatic prostate cancer. *Genomics*. 1996;35:46-54.
- Fujiwara Y, Obata H, Kuroki T, Koyama K, Tsuchiya E, Monden M, et al. Isolation of a candidate tumor suppressor gene on chromosome 8p21.3-8p22 that is homologous to an extracellular domain of the PDGF receptor beta gene. *Oncogene*. 1995;10:891-5.
- Goldstein DJ, Oz MC, Rose EA, Fisher P, Michler RE. Experience with heart transplantation for cardiac tumors. *J Heart Lung Transplant*. 1995;14:382-6.
- Michler RE, Goldstein DJ. Treatment of cardiac tumors by orthotopic cardiac transplantation. *Semin Oncol*. 1997;24:534-9.