

Endaural tympanoplasty without flap

A report on 34 cases

By J. J. SAMMUT (Malta)

Introduction

The most carefully planned and executed operation on the ear is a failure as far as the patient is concerned if the cavity collects debris and discharges for months and years afterwards. According to Mawson (1967), twenty-five per cent of radical mastoid cavities fail to heal, remain infected and discharge persistently after operation. Of 428 tympanoplasties done by Portmann (1963) between 1959 and 1962, only 75 per cent achieved perfectly dry cavities.

The ideal procedure should therefore:

- (1) remove disease,
- (2) restore hearing and
- (3) avoid an unsatisfactory residual mastoid cavity.

In addition it should be a procedure which can be safely recommended to the otologist with limited experience of microsurgery.

In Combined Approach Tympanoplasty (Jansen, 1963) the tympanic cavity is cleared from the mastoid approach through an enlarged aditus medial to a thinned-out posterior bony meatal wall, which preserves the natural shape of the meatus. A new tympanic membrane is also fashioned. The operation satisfies the first three requisites above; however, it is an operation which requires high technical skill and which is safe only in the hands of those especially experienced to perform it. For those who do not favour it or who do not feel sufficiently experienced, an alternative is offered here, after which a comparison between the relative merits of the two operations will be made.

In the tympanoplasty technique described here, the posterior bony wall of the auditory meatus is demolished, but the posterior meatal skin, instead of being fashioned into any sort of flap, is dissected bodily forward onto the anterior meatal wall for the duration of the operation, after which it is returned to its original position. A fascia graft is then inserted permeatally, and blood-clot eventually obliterates the post-meatal cavity. Cases of simple permeatal myringoplasty are therefore excluded from this series.

None of the individual steps described are new or original in themselves. Basically they constitute the operation described by Daggett in 1949, (conservative mastoid with preservation of soft meatus) to which the

J. J. Sammut

physiological principles of Tympanoplasty (Wullstein, 1953) are adapted. Temporalis muscle fascia is used as scaffolding for the new tympanic membrane.

The cases presented are few in number (thirty-four), but consecutive and well documented. The classification corresponds broadly to that of Wullstein: (Type I, for simple Myringoplasty is not considered in this series), Type II for graft on incus, Type III for graft on head of stapes, Type IV for graft on stapes remnants, and Type V for fenestration of the lateral semicircular canal.

Ten cases of extended Type I are presented, five of Type II, seventeen of Type III, and two of Type IV—each being an individual adaptation of a general procedure here described as *Endaural Tympanoplasty Without Flap*. Twenty-nine cases, where all steps of the procedure were strictly adhered to, were successful in every way, and five, where one or other detail was not observed, are considered technical failures. The reasons for failure will be shown. The illustrations are biro-sketches by the author, drawn from memory of actual operations.

Indications for ETWOF

These are the usual ones for classical tympanoplasties with flap.

(1) Six months' dry central perforation causing deafness, when the state of health of the middle ear is still in doubt (Extended Type I).

(2) Central perforation persistently moist in spite of healthy upper respiratory tract (Type II, III or IV or Extended Type I). The patient usually wants the operation even if for aesthetic reasons alone, independently of hearing.

(3) Middle-ear discharge of doubtful duration—where a simple Schwartze is likely to fail and lead to a second operation (Types II–IV or Extended Type I).

(4) Chronic middle-ear suppuration with or without cholesteatoma (Types II–IV or even an Extended Type I).

Non-indication

Dry central perforation not causing deafness, where the patient does not especially request the operation.

Contraindications

This must be looked upon as a closed-cavity operation, which is unsafe, in the presence of:

- (i) Labyrinthine fistula.
- (ii) Meningeal involvement, and
- (iii) Malignancy.

Note: Cholesteatoma was encountered in only one of these cases.

Endaural tympanoplasty without flap

ENDAURAL TYMPANOPLASTY WITHOUT FLAP - J.J. SAMMUT

Case No 19....
 Name C.V....
 Age 18.....
 Op. Date 15.7.70
 Type I (ext'd)

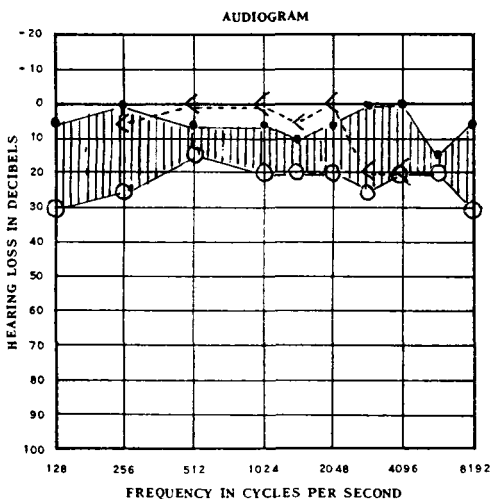


FIG. A.

ENDAURAL TYMPANOPLASTY WITHOUT FLAP - J.J. SAMMUT

Case No 14....
 Name C.Sc....
 Age 19.....
 Op. Date 25.3.70
 Type II

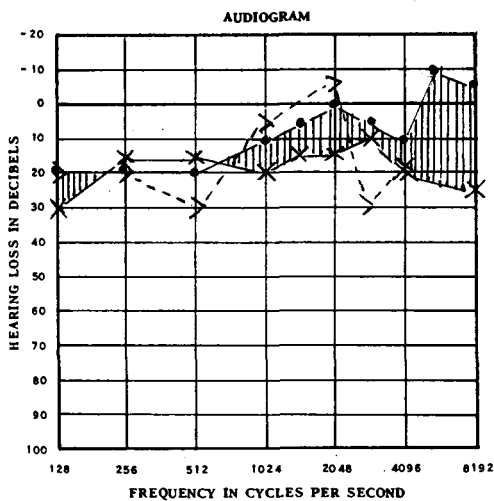


FIG. B.

J. J. Sammut

ENDAURAL TYMPANOPLASTY WITHOUT FLAP - J.J. SAMMUT

Case No. 13...
 Name . E.D...
 Age . 24...
 Op. Date 20.3.70
 Type III

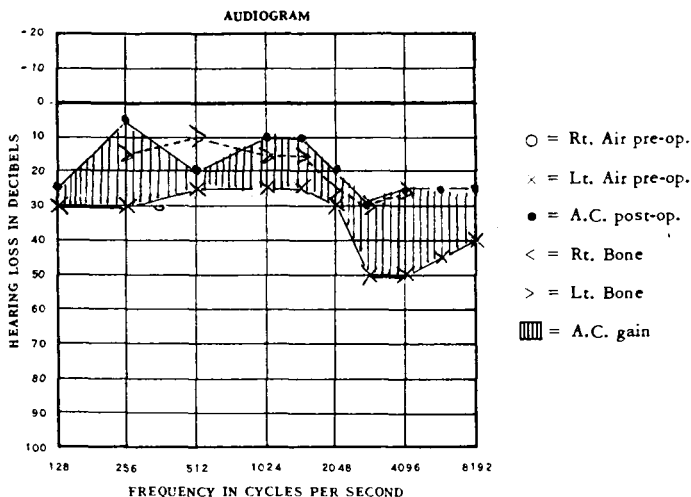


FIG. C.

ENDAURAL TYMPANOPLASTY WITHOUT FLAP - J.J. SAMMUT

Case No. 1-34...
 Name AVERAGE...
 Age 12-54...
 Op. Date 13.1.69
 to 22.1.71

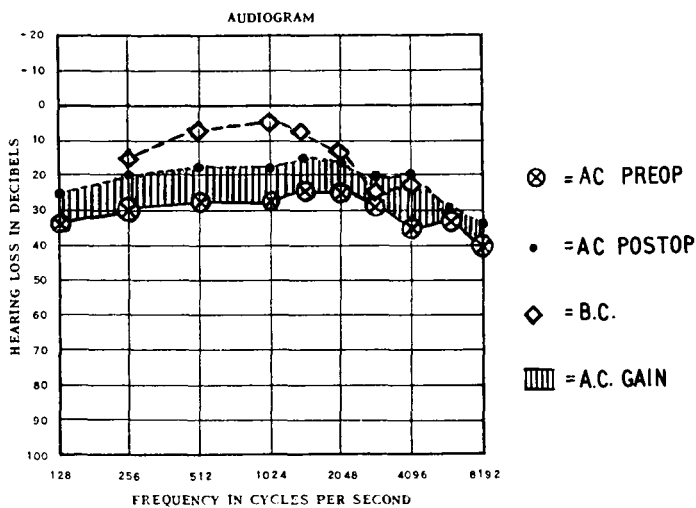


FIG. D.

Endaural tympanoplasty without flap

The operation

Each individual operation was approached with an open mind and the tympanoplasty type decided upon after satisfactory operative exposure.

Anaesthesia. This was always general with hypotension: pentothal and scoline induction followed by endotracheal fluothane. For the main part of the operation systolic BP was kept at 100–70 mm.

Final inspection. Do not infiltrate the soft tissues initially, but start with a final and definitive examination and suction clearance, using a Zeiss microscope. This might have proved unsatisfactory on a sensitive patient when conscious, especially in the presence of a marked anterior meatal convexity (Figs. 1, 2, 3), which can now be drilled or curetted away. Sometimes the anterior margin of the tympanic membrane can be seen if viewed from a very acute posterior angle. If this inspection is held back till after infiltration, the meatal walls are swollen, narrowing the meatus and obscuring the drum margins. Once a perforation has been confirmed, most of or all the de-epithelialization of the tympanic membrane can be done at this stage. Epithelium peels off chalk patches very easily in continuity with the rest of the surface—actually it is the easiest part to ‘skin’. A width of 6 mm. of meatal skin all round is also de-epithelialized.

Local infiltration with haemostatic solution may be then proceeded with as for any other endaural operation.

Incision. (Fig. 1). For all cases an incision is made from the tragal angle out and up in front of and parallel to the helix for about 2 cm. Cutting through cartilage is avoided. Into this external incision a self-retaining retractor is inserted, and an adequate portion of temporalis fascia removed for grafting. (The author learnt personally of fascia as graft material from Plester (1963), who stressed as a main advantage its low metabolic rate. Storrs had also advocated its use in 1961. It has always been used since.)

In cases of proposed myringoplasty where uncertainty still exists as to the extent of disease in the tympanic cavity, the graft taken is as large as the opening permits. The graft is kept flat in a press; for this two microscope slides and two clothes-pegs prove effective. The skin incision (Fig. 1) is then extended inwards into the meatus and obliquely backwards to the osteochondral junction on the posterior meatal wall, then, cutting onto bone, where the subcutaneous tissue is thinner, along the back and floor of the meatus as for any endaural mastoidectomy. If the endaural part of the incision is made too near the meatal entrance, thick fatty connective tissue will be included with the skin to be mobilized. This is undesirable and tends to obscure the retromeatal view of the middle ear. It also leads to constant handling which may result in a tear along the meatal floor, thus forming a flap—the very thing the operation seeks to avoid.

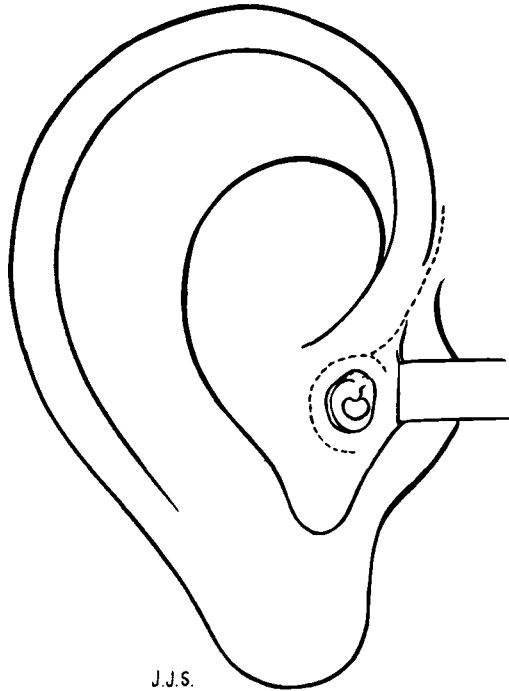


FIG. 1.

First and only incision (dotted line) is described in 3 parts: (a) External, (b) Internal, at osteochondral junction, and (c) Forward Extension to latter. Note central perf. and ant. meatal bulge.

Along the meatal roof a small secondary incision is cut at an angle with the first (Fig. 1). This allows a small triangular portion of roof skin to be reflected forward and help uncover the lateral attic wall.

With a periosteal elevator the bone of the suprameatal triangle and lateral attic wall are bared and the retractor re-inserted accordingly (Fig. 3). The anterior jaw of the retractor holds the small triangular portion of skin forward. *No further incision is made—and therefore no flap cut—for any type tympanoplasty—throughout the operation.* The purpose of the forward extension is to allow free downward displacement of meatal skin as well as for forward retraction.

By now whilst still on the stretch, the tympanic membrane and surrounding meatal skin should have been completely de-epithelialized and the perforation trimmed: this could prove very difficult if left till later when meatal skin and drum have become mobilized and flabby. The medial, i.e. 'tympanic' edge of the anterior meatal skin is rolled outwards.

The posterior meatal skin together with the posterior half of the drum is now very carefully detached and dissected forward. When the pars flaccida is reflected forward, the entrance to Prussak's space comes into view (Fig. 4).

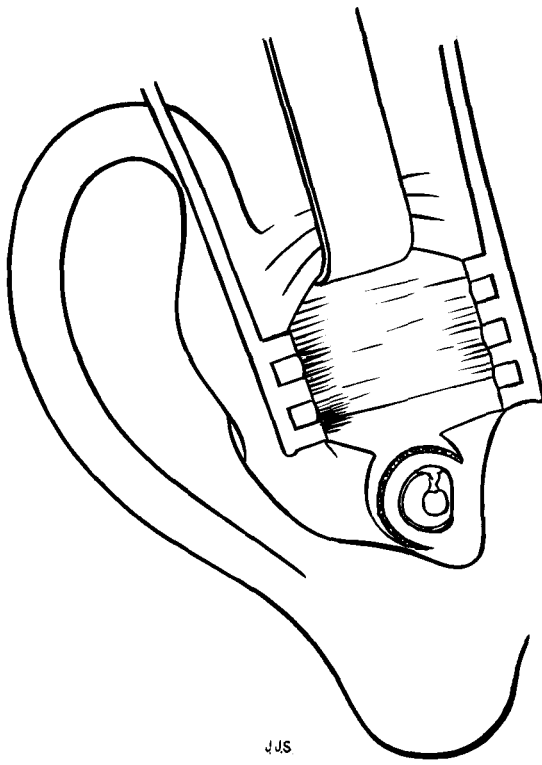


FIG. 2.

Incision (mainly external portion) retracted to expose temporalis muscle fascia.

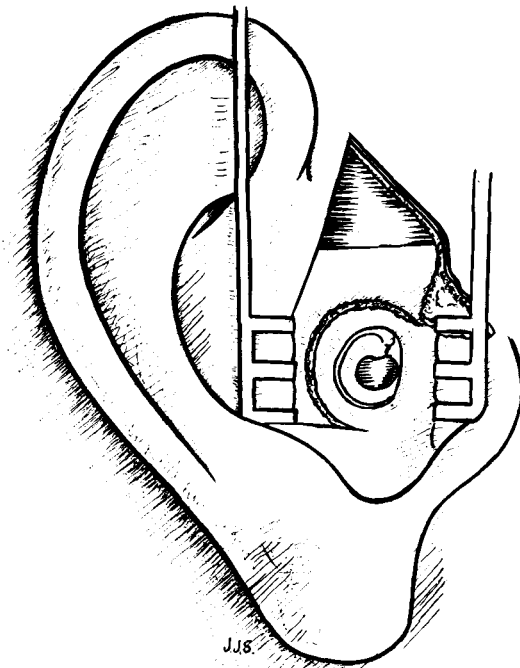


FIG. 3.

Retractor re-inserted lower down giving better view of meatus and drum. Triangular portion of ant. meatal skin held forward. De-epithelialize at this stage.

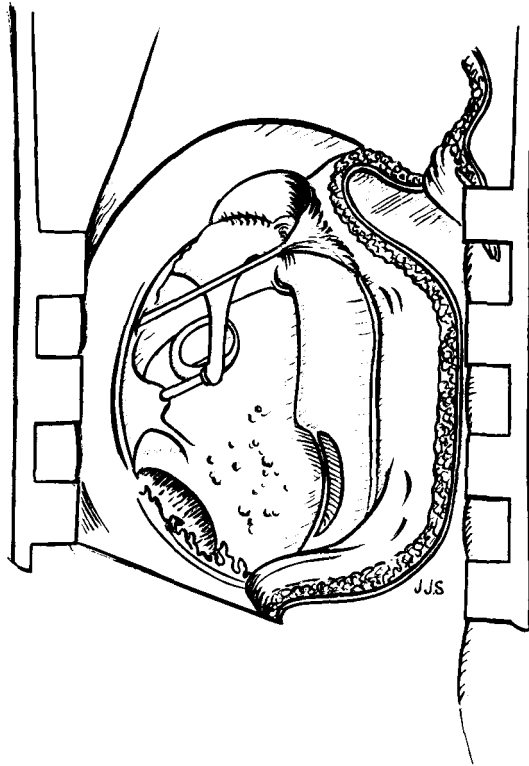


FIG. 4.

Post. meatal skin dissected bodily forward showing a healthy middle ear needing no further surgery. Prussak's space also exposed. (Extended Type I)

It is now possible to assess for continuity of the ossicular chain. When the history is that of a dry ear for several months, and no discharge can be seen or aspirated from the posterior attic pouch (Sammut, 1968), (isthmus tympani posticus of Proctor, 1964) and other accessible parts, and in the absence of an attic perforation or cholesteatoma, it is safe to regard the middle ear as healthy. Thickened and knobby mucosa over the promontory may be regarded as reactionary to exposure from a central perforation. Curetting a meatal overhang (as in stapedectomy) can give further information. The meatal skin and posterior half of the drum are put back into place, and the fascial graft applied (Extended Type I). In these doubtful cases the author prefers this routine to the burring of inspection holes over attic and antrum. When the perforation is very large or subtotal, the mucosa over the promontory may be scarified and the graft allowed to adhere to it. This lessens the chances of re-perforation and does not prevent maximum hearing results (A-B gap closed in 8 cases out of 10). Mucosa grows over the medial aspect of the graft and around the artificial adhesion.

Endaural tympanoplasty without flap

If, on inspection as described, the middle ear appears unhealthy, or there is discontinuity of the ossicular chain, or, as occurred in one of these cases, a fixed stapes, then extended Type I is abandoned as obviously inadequate. Time spent on these explorations is never wasted, and the amount of active disease that can be present in the middle ear even behind a completely intact drum can be quite surprising. Needless to say, in the presence of a marginal or attic perforation—whatever the condition of the rest of the drum—the attic and antrum should always be explored.

Once all thought of extended Type I has been given up, one must determine what other type of tympanoplasty should be adopted.

When there are no recognizable structures to be seen in the middle ear, owing to masses of granulations (Fig. 5), the process of elimination should begin at the incudostapedial joint region, which is carefully cleaned of granulation and adhesions. If the joint is still intact (Fig. 6) and functional, an effort is made to preserve it and the rest of the ossicular chain, and a Type II attempted.

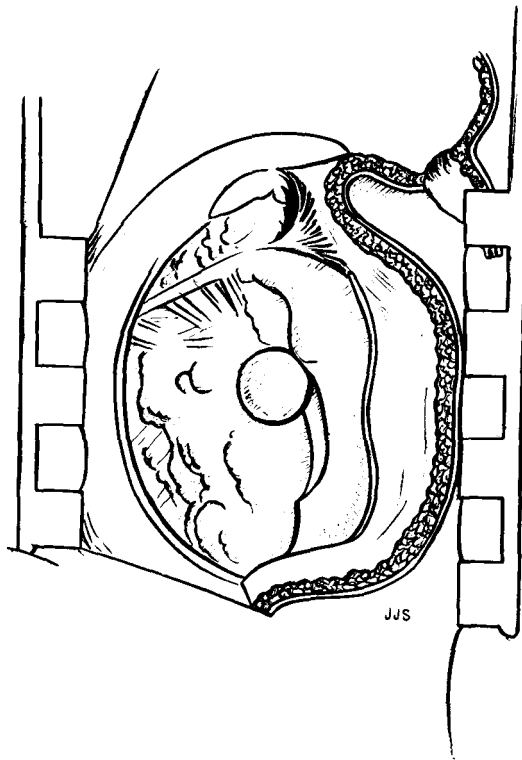


FIG. 5.

Post-meatal skin dissected forward, middle ear is a mass of fibrosis and granulations with one large polyp. Exposure of incudo-stapedial region will determine type of tympanoplasty needed.

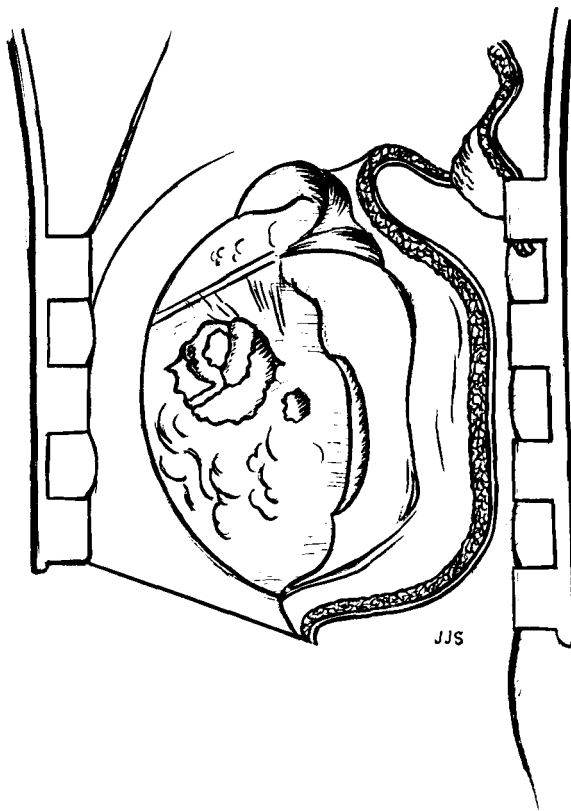


FIG. 6.

Compare Fig. 5. Large polyp removed. Window cut out in fibro-granular tissue showing a functional incudo-stapedial joint. Try a Type II.

An infallible confirmation for the integrity of an ossicular chain is the 'round-window reflex'.

As in all other endaural procedures, the antrum and all cells can be exposed by this route (Fig. 7). Should the latter be exceptionally extensive posteriorly, a complementary postauricular incision could always be made, without compromise to the flapless operation. (This was never found necessary in operations on 'chronic ears' whether a flap was cut or not.)

Only irreversible disease is removed, that is, pus, cholesteatoma and large or medium-sized polyps. Small and diminutive polyps which are not obviously retaining disease and which, owing to their situation, are hazardous to remove, are safely left. When the middle ear, including the mastoid, has been rendered healthy, and a Type II is still possible, the posterior meatal skin is returned to its place, now lying 'in mid-air' between the meatus in front and mastoid cavity behind.

Endaural tympanoplasty without flap

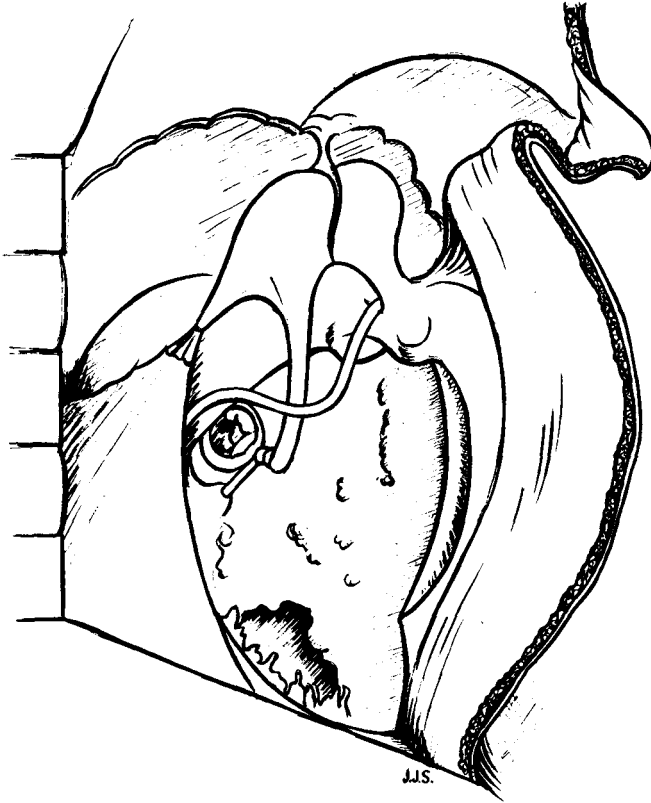


FIG. 7.

Compare Fig. 6. Bridge lowered, antrum and attic cleared. Minor granulations, especially around stapes, not disturbed.

On removal from its press the graft is found to be of just the right consistency to be manageable. It is also of a size large enough for cutting into shape. The graft is placed over the tympanic membrane remnant and anterior meatal wall and in contact with the incudal body or long process (Fig. 8). In the absence of sufficient support from the posterior drum remnant, the posterior part of the graft comes to lie on the lateral semicircular canal and facial ridge (Fig. 8, alternate position). As the graft is mesodermal, and contains no squamous epithelium, it is not important how far it extends into the aditus. It should, of course, extend beyond the round window below. If insufficient tenting is provided by a malleolar stump, a sausage-shaped piece of 'Sterispon' (or Gelfoam) (McGuckin, 1958) is placed along the hypotympanum from the round window to the eustachian orifice, keeping the graft away from both. It seems that the sterispon eventually resorbs, leaving an air-tunnel which protects the round window from direct stimulation and into which

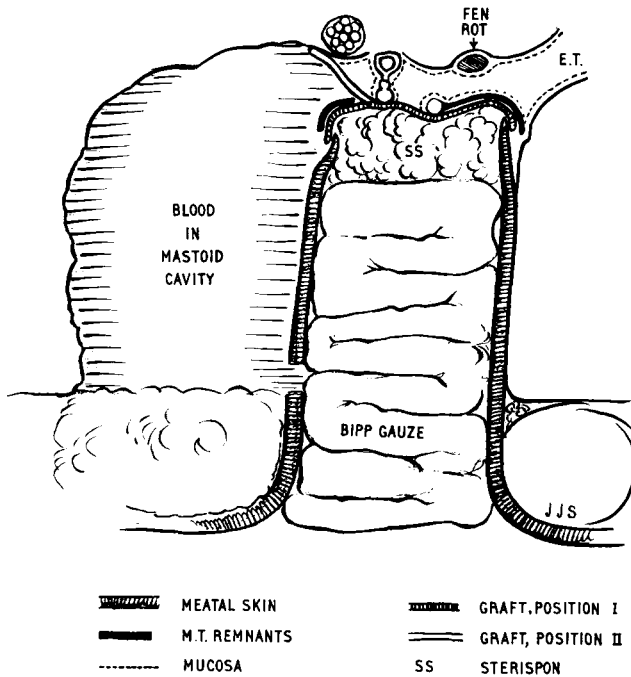


FIG. 8.

round window vibrations disperse. Because hearing improves with the passage of time, it is presumed that the tunnel comes to be lined by mucosa permanently (post. op. AC = BC in 3 cases on 5). It is therefore seen that one important advantage of the approach (for all types I-IV) is that the long process of the incus and incudostapedial joint, (if necessary by cutting away bony overhang) can be properly inspected at an early stage. Portmann (1963) lays emphasis on early examination of 'the region of the oval window' in dubious cases, and Guillon and Batisse (1963) stress the same point.

If, as often happens, the incus is found eroded and out of contact with the stapes, without transmission of any movement (Fig. 9), type II is abandoned. When the tympanic cavity is so packed with granulo-fibrous tissue that it is likely to be a long-drawn-out and hazardous procedure to remove it and only doubtfully save the chain in the end, it seems wiser to eliminate a type II outright. Attic and antrum are opened up after complete removal of the bridge and complete lowering of the facial ridge, incus is removed, together with the head of the malleus. The attic and antrum are now properly cleared, and a type III or IV operation completed, as the case may be.

Much emphasis has been laid by the promoters of the combined approach tympanoplasty (Jansen, 1963) on the complete clearance of

Endaural tympanoplasty without flap

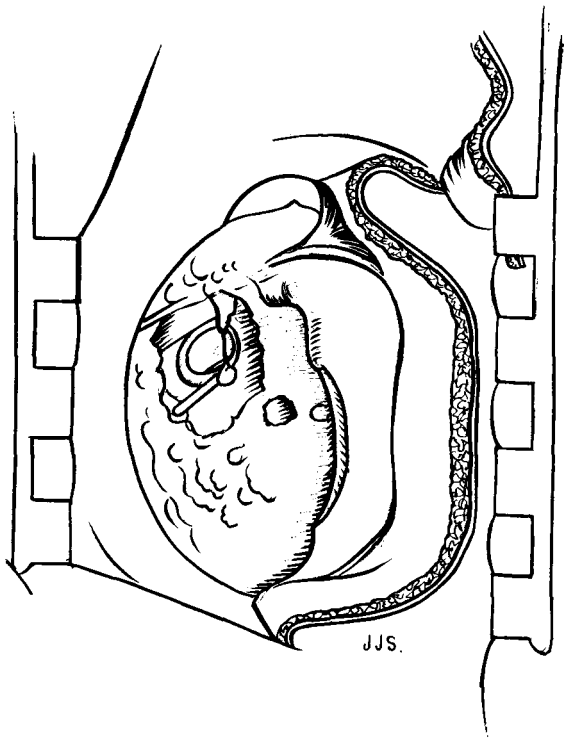


FIG. 9.

Post-meatal skin dissected forward. Artificial window in granular mass shows thready, non-functional connection between incus and stapes. Type III indicated.

the superior facial recess. If it is suspected that cholesteatoma has invaded the superior facial recess, not only is it possible to expose this from the lateral (endaural) aspect, but if necessary a facial decompression of the entire vertical portion can be performed too (Fig. 10). Also from this approach it is possible to remove quite a considerable amount of bony overhang lateral to the sinus tympani (inferior facial recess) before actually exposing the facial nerve sheath from the front. This latter procedure is not possible from the CAT approach, i.e. when the bony meatal wall is preserved. The hypotympanum is quite easy to expose. The weak point, if it can be called that, of this approach, is the difficulty in viewing the tubotympanic region. But this is a disadvantage more theoretical than actual. If the tympanomeatus is retracted forwards and outwards with a blunt hook it gives a good 'diagnostic' view of the eustachian orifice area, sufficient for suction or removal of polypi. The sucker-tip itself can also act as a retractor (Fig. 10). Even here, one should remove polyps and granulations only inasmuch as they harbour disease (pus) and/or interfere with function; otherwise, by themselves they are a

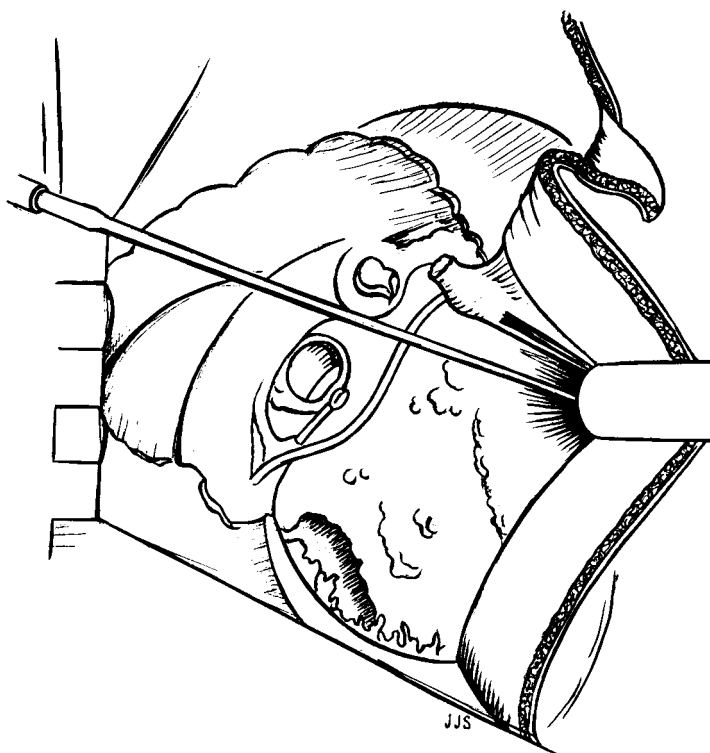


FIG. 10.

Compare Fig. 9. Bridge, incus and head of malleus removed. Antrum and attic exposed. Post-meatal wall retracted forwards and out. Sucker-tip in tubo-tympanic orifice. Sup. facial recess and hypotympanum exposed.

healthy process, incidentally also useful for the nourishment of a graft. Their meticulous removal for their own sake can be time-consuming, hazardous to fine structures, and not justified by results.

When patching a very large perforation in any approach or type of tympanoplasty, it has always been the author's aim to scarify the promontory for attachment and vascularization of the graft, and this has not prevented even maximum (i.e. zero-loss or higher) hearing results being obtained. But whether or not this is done, and whether or not chain reconstruction is fashioned is of course a question of individual preference, equally adaptable to the procedure under discussion. Nothing is gained by excessive toilet in and around the stapes, and much harm can be done. So long as the gross polypoid granulations are removed and mobility ascertained, the stapes can be safely left (Fig. 10). It is useful to produce a tiny bleeding surface on the articular facet of the head of the stapes if a graft is to be applied to it direct. 'Juers (1954) has termed this as "myringo-

Endaural tympanoplasty without flap

stapediopexy” while Zollner (1959) calls it the “columella effect”. Since the lever effect of malleus and incus contributes less than 2·5 decibels to sound pressure transformation, the hearing after myringostapediopexy by “columella” can approximate normal’. Some Sterispon (or Gelfoam) is rolled into a sausage and placed along the hypotympanum from round window to eustachian tube as for Type II above.

The posterior meatal skin with any tympanic remnants is returned to its natural position. The graft is then inserted permeatally, and if necessary, adjusted postmeatally. Ideally (Fig. 11) the graft should overlap the following structures (in Type III or IV): The remains of the bared tympanic membrane and a 6 mm. width of anterior-inferior tympanic bone around it and the lateral aspect of the facial ridge. It must, of course, come in contact with the stapes (or remnants, in Type IV) directly or through an intervening prosthesis. The graft can obtain nourishment by adhering to the mucosa of the facial canal and promontory. Adherence does not prevent maximum hearing results. Out of the 17 cases of myringostapedopexy the A-B gap was closed for speech in 9. By definition, there is no danger of cholesteatoma (keratin) spreading from fascia. The graft is prevented from obliterating the hypotympanum between round window and eustachian tube by the presence, and later absorption, of the sterispon ‘sausage’. The anterior meatal skin is now

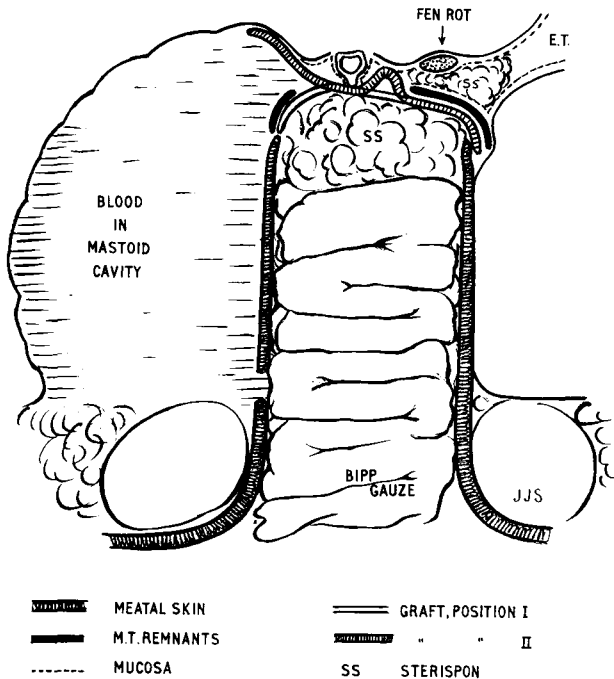


FIG. 11.

J. J. Sammut

rolled back over the graft. Some pellets of sterispon are placed, through the meatus (now again of normal shape) directly upon the graft, and the meatus packed, with moderate pressure, with half-inch BIPP gauze (Figs. 11, 12), care being taken that no gauze finds its way posterior to meatal skin either into the antrum or, laterally, into the meatal incision. The shape of the meatus is thus preserved. This is very important and applies to any type of Endaural Tympanoplasty Without Flap.

At this stage in a traditional 'flap' operation we would be left with the bogey of a mastoid cavity. This has presented no problems here; neither did it in Daggett's cases. Even as one watches, the mastoid cavity fills with blood, and no steps are taken to prevent it doing so. As the meatal part of the incision is not sutured, and there is some shrinkage of the posterior meatal skin by now, a gap is left between medial two-third and lateral third of the posterior meatal skin. There is usually a similar interval between the medial (tympanic) edge of the posterior meatal skin and the outer surface of the graft. Both gaps become bridged over by blood-clot alone (Figs. 8, 11, 12). In addition, as the meatus is only loosely packed, there is ample opportunity for drainage even in the most septic of cases. Some penicillin-sulphonamide powder ('DIDRO' Grunenthal) is insufflated into the wound, (the patient is also given full doses of penicillin systemically) and a stitch or two closes the external part of the incision. No attempt is made to suture the meatal skin itself, as this

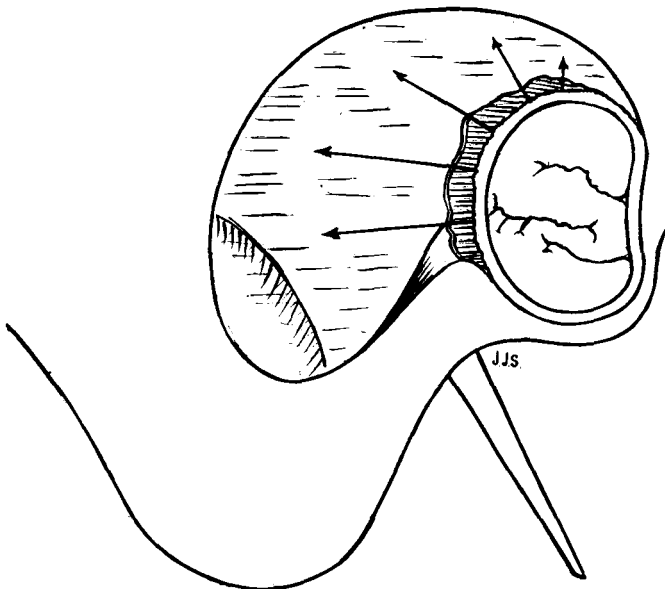


FIG. 12.

Schematic view of skin back in place and meatus packed with BIPP gauze. Graft protrudes into aditus and attic. Arrows show eventual lines of traction of organized blood clot. Ant. and inf. meatal skin remains fixed to tympanic bone.

Endaural tympanoplasty without flap

is not only unnecessary but hazardous. No plastic sheeting is used inside the ear and no drain tube left in the wound. A pad and bandage are applied and usually removed after one or two days, the patient discharged and told to puff the powder lightly over the stitches twice daily.

The routine is versatile and can be applied to any type of tympanoplasty by an orderly process of elimination, though it will be appreciated that, once a Type II has been opted for, the operation will be longer and more meticulous. A similar process of elimination had been followed previously in 'flap' operations.

There was never any rise in temperature at any time after the operation beyond 99 °F for the first day or two. Neither was there ever any pain.

Stitches came out five days after the operation. Fourteen days post-operatively the BIPP pack was removed, quite painlessly, and the meatus inspected under a Zeiss microscope. Strong suction should be avoided (V. Case 8: D.S. below). The entire incision, external and endomeatal, was completely healed as if by first intention, and the meatus was to all intents and purposes normal. The region of the tympanic membrane was covered in a shiny white jelly, due to the sterispon by now soaked in serum. This was not disturbed. The patient was comfortable and happy enough to co-operate in C.V. hearing tests, and a second BIPP pack was inserted for a further fortnight after which its removal was again absolutely painless, and the ear was left to its own resources. After two days or so of fresh air it was bone-dry and already, in some cases (q.v.) showed marked improvement in hearing.

In the first two cases of the series the BIPP gauze, besides filling the meatus, was also tucked back through the meatal incision in the hope of preventing the formation of granulation tissue. Precisely the opposite occurred: by preventing the edges uniting across the blood clot, not only did granulations form, but so did polyps large enough to fill the meatus. Fortunately, removing the polyp remedied the situation immediately in each case. From the third case onwards the pack has been strictly limited to the meatus and there has been no further trouble with granulations, a smooth epithelial surface resulting, even only a fortnight after the operation, covering drum and meatus and continuous with that of the pinna.

In none of the cases was there any stenosis: in fact, the meatus appears to be uniformly wider at each successive examination, presumably from the recession in all directions of the blood-clot around it (Fig. 12). No mastoid cavity or any other pockets ever formed when the routine was observed. Six weeks after the operation the external part of the scar is just noticeable upon close scrutiny. Aeration of the mastoid does not seem to be necessary in these cases, as indicated later (Case 4: I.C.), presumably as there is no lining from the graft or mucous membrane left in the mastoid, requiring it. Complicated procedures aimed at ventilating the mastoid do not therefore seem necessary.

J. J. Sammut

In all the cases of this series the incision was made into healthy skin. However, it may be of interest that some of the previous (flap) cases had been suffering from otitis externa or eczema of the meatal opening which was kept active by the middle-ear discharge. It was therefore hopeless trying to cure the former without first removing the exciting cause, and, after usual methods for curing the otitis externa had failed, tympanoplasty was performed regardless, and both conditions healed together.

The advantages of fascia over skin for grafting in these cases

First of all, fascia has a lower metabolic rate than skin and therefore longer survival potential. Vascularization is given a better chance and there is less likelihood of reperforation. As the posterior margin of the graft comes to lie on the facial ridge and aditus, it seems that epithelium grows towards it from the posterior meatal skin across the anterior surface of the blood-clot to grow over the lateral surface of the graft. However, even if the graft had extended back deep to the clot, it would still be quite safe and likely to grow over the bone surface. As we are here concerned with a fascial, i.e. mesodermal, tissue, this would not matter in the least, as it is not cholesteatoma-forming, and the surface of the clot is continuous with the exposed portion over which new epithelium grows. In the case of an ectodermal (skin) graft extending deep to the blood-clot, the result would be disastrous as cholesteatoma would run wild in the closed-off mastoid cavity. So, for this operation anyway, fascia or other mesodermal tissue, such as perichondrium or vein, is safest.

Moreover, the use of a skin-graft, whether pedicled as a flap or free, presumes sacrificing part of the meatal structure or creating a postauricular wound.

In six consecutive cases (Nos. 20 to 25) a layer of gauze was included in the press with the graft. As a result, the graft was perfect to manage when taken out, but, as events proved, over-desiccated. Nos. 20 and 23 soon reperforated, whilst Nos. 22 and 25 are still intact at the time of writing (3 months later) but healing (by replacement) very sluggishly. The remaining two cases gave no trouble. In all six cases the meatus is dry and of normal shape and the hearing level maintained or improved.

Main points for the success of the operation

(Most of these have been repeated ad nauseam in descriptions of the classical tympanoplasties with flap. Others apply particularly to Endaural Tympanoplasty Without Flap.)

(i) Do not infiltrate before thoroughly inspecting the ear. Infiltration causes meatal swelling and obscures drum margins.

(ii) Keep to the line of incision described and avoid cartilage. The incision facilitates downward and upward, as well as forward, displacement of meatal skin.

Endaural tympanoplasty without flap

(iii) Cut fascia initially as large as possible—this will then cover any area desired, and can always be cut down to size.

(iv) Take graft at start of operation and keep under moderate pressure. This gives it the right shape and consistency and keeps it fresh.

(v) Ensure full visibility of tympanic membrane for marginal disease and for complete de-epithelialization.

(vi) De-epithelize before freeing meatal skin. Difficult and unreliable if done later.

(vii) Remember to roll out medial edge of anterior meatal skin—this prevents it spreading deep to fascia, over which it should come to lie.

(viii) Inspect incudo-stapedial joint region at the earliest opportunity and plan accordingly. This avoids waste of precious time trying to preserve what would later turn out to be a useless incus and malleus. Conversely, it prevents one taking for granted as destroyed an incus, buried in granulations, which is actually intact.

(ix) Of course, remove all disease from the middle ear, including attic and antrum and all other accessible pockets. In the rare event of diffuse mastoid cells, pride is swallowed and a complementary postauricular incision is made, without prejudice to the integrity of the meatus. If this is necessary but not done, the basic purpose of the operation, i.e. the removal of all disease, is defeated.

(x) Clean around the stapes but only enough to ensure mobility and a good 'take' on the head for a graft or on the footplate for a prosthesis—any more might cause unnecessary postoperative giddiness at best, or, at worst, labyrinthitis.

(xi) Remember to place the sterispon 'sausage' along hypotympanum between round window and eustachian orifice. This will protect the round window and leave a canal for dispersal of round window vibrations.

(xii) When the graft is placed on the drum it must cover all the perforation within a wide scarified area all around—this makes sure squamous epithelium does not grow into the middle ear.

(xiii) When the graft is placed over the medial wall of middle ear, it should cover, with a wide apron all around, body of incus (type II), head of stapes (type III), round window and hypotympanum (over 'sausage') eustachian orifice and facial canal. It need not cover the antrum. External vibrations are transmitted to the stapes, and the round window is protected whilst its own vibrations are dispersed into the air tunnel left by the sterispon 'sausage'.

(xiv) Remember to roll anterior meatal skin back into place over the graft—to maintain layer relations and facilitate healing.

(xv) Don't tuck BIPP gauze back further than meatal skin. This prevents the formation of a pocket medially and polyps laterally.

J. J. Sammut

Comments

All types III were done without reconstruction of the ossicular chain or the use of prostheses, and the graft was placed directly over the head of the stapes and promontory leaving only a small tympanic cavity—the size of the sterispon sausage—for protection of the round window—and a small vibrating new drum above. Yet all these cases ended up either with (absolutely) excellent hearing, or, where bone conduction had been poor, to within 20 dB of this for the speech range. It therefore appears in effect that the ‘sausage’ helps the development of an efficient air tunnel for protection of round window and dispersal of its vibrations, and that the limited area of vibrating membrane above the promontory is sufficient for a transformer mechanism. Because the graft adheres to the promontory there is very little likelihood of a reperforation. The effective (i.e. sound-conducting) ‘tympanic membrane’ is that part of the graft limited by: anterior-superior margin of tympanic sulcus, promontory, facial ridge and horizontal portion of the facial canal.

All these operations were done in one stage. As far as the patient is concerned, in this particular environment anyway, a second operation presumes a failure of the first.

All cases dry to date (20 February 1971).

All cases have good hearing to date even where there is no actual gain.

Two reperforations to date—Longest post op. duration 25 months.

Where the rules of procedure were complied with, the results were excellent curatively, functionally and cosmetically. In two cases one or other of the steps were not observed properly:

Case 5

A.S., after the patient had his stitches out five days post-operatively, he failed to report again till sent for six months later. He had apparently removed the pack himself at some stage because he decided his ear was alright and his hearing good. There was a polyp inside the meatus originating from the incision which he was quite happy to leave. He reported on 2 March 1971. His meatus is normal, m.t. dry and the A-B gap closed.

Case 8

D.S., type III done on 21 November 1969. He pulled his own BIPP pack out twelve days after operation and would not have another put in. The meatus was cleared out under an operating microscope and blood-clot was unintentionally sucked out through the meatal incision. He went overseas for three months and when seen again presented a dry ear showing a skin partition, incomplete laterally, between meatus and epithelialized mastoid cavity—obviously this had not filled with blood again after suction and epithelium had grown around the posterior skin edge. The hearing is back to its pre-operative high level (actually gaining for higher notes) and there is no sign of cholesteatoma formation yet. He was seen again in November 1970 (12 months post-op.). The ear

Endaural tympanoplasty without flap

was bone dry and the partition very low, hardly separating the meatus from a very small dry mastoid cavity. The good hearing level (at 5 dB for speech) was maintained.

Two of the cases deserve special mention as they seem to open up new possibilities:

Case 4

I.C., aged 49. This lady had had a left stapedectomy for otosclerosis five years previously overseas. The ear went septic and broke down soon after and it was for chronic discharge that she presented herself. At operation on 18 April 1969 there was hardly any drum left. The tympanic cavity was occupied by a fibrogranular and purulent mass, embedded in which were a carious incudal body, a wire-teflon prosthesis and malleolar head. The oval window was, mercifully sealed off with thick fibrogranular tissue. This was not disturbed but otherwise the whole of the middle ear was cleared and a graft placed direct over the oval window. The approach was the one described here. She had a bone-dry ear with a perfect 'take' within six weeks. As expected, there was no improvement in hearing, and this rather depressed her. She was in favour of undergoing a third operation to improve her hearing, and this was done on 6 February 1970. As there were no ossicles left, and it was not thought advisable to disturb the oval window 'obturator', the operation of choice seemed to be a fenestration of the lateral semicircular canal. It was the easiest thing to cut a Lempert (1938) flap in the isolated posterior meatal skin now of normal thickness at the scar, and this was done, exposing a mastoid cavity. This case might illustrate a good line of action in similar conditions.

The fenestration operation also provided an opportunity for discovering the fate of the blood-clot. There was here no sign of a haematoma (9½ months after the author's first operation) but many fine fibrous strands were tethering the posterior meatal skin in all directions to the walls of the mastoid cavity. (The 'Collagen' mentioned by Rambo (1963)). The bone was otherwise bare with no obvious signs of secondary epithelial covering. The cavity was dry with no 'glue' or other pathology usually attributed to non-aeration. Neither was there any cholesteatoma. It would seem, therefore, that, so far as it is possible to judge from this particular case, it is quite safe to leave a closed bony cavity so long as it is not carpeted by skin or mucosa, and that the use of plastic sheeting is not essential.

Case 7

R.F., aged 30. This man, an oil driller working in N. Africa, came because of discharge from his left ear, continuous since childhood, in spite of two previous operations (aet 8 and 10). His middle ear was disorganized and full of polyps and pus; there was no cholesteatoma but a large 'radical cavity'. There was still some good posterior meatal skin in the outer third. This was elevated and pushed forward as was done with the whole posterior meatal skin in the other cases. This still left an epithelium-lined mastoid cavity, which was therefore thoroughly curetted to the bare bone, as far forwards as the lateral semi-circular canal. The operation (Type III) was done in the usual way and a fascial graft applied.

J. J. Sammut

When the posterior meatal skin remnant was replaced, BIPP gauze was inserted permeatally as usual, care being taken not to tuck it back into the mastoid cavity. Blood-clot did the rest. The meatus and new drum were bone-dry and of normal appearance 20 days after the operation with 20 dB hearing improvement for the speech range. It would seem from this that the retracting action of the blood-clot does not have effect before a fairly resistant dermal covering forms on its anterior surface.

Since drafting this paper the same technique was followed on another broken-down old 'radical' (No. 21) with a foul middle ear and mastoid cavity, but care was taken this time not to disturb the meatal wound too early. Two weeks postoperatively there was a perfect graft 'take'; a fortnight later the meatus was bone-dry and normal in shape, and has remained so since. The hearing, at 20 dB pre-op. for speech, is unchanged so far (4 months post-op.).

Comparison of the operation described with CAT

Combined Approach Tympanoplasty applies the physiological principles of tympanoplasty, i.e. it removes disease from the middle ear and fashions a new tympanic membrane in such a way as to restore hearing. Its special claim is the possibility of preserving the posterior bony wall of the meatus and at the same time visualizing and cleaning the whole tympanic cavity, including the eustachian tube orifice, the hypotympanum and the superior facial recess, from the posterior or mastoid approach through a downward extension of the aditus between the vertical portion of the facial canal and the thinned-out posterior bony wall. In this way, it is claimed, the middle ear is more thoroughly cleared than by any other method, and no open mastoid cavity is left to fill with keratinous debris necessitating frequent attendances. Also, it is said, danger to the facial nerve is negligible in experienced hands.

The operation has been adopted enthusiastically by some, whilst receiving varying degrees of criticism from others. Baron's (1967) remarks are quite devastating. This author (J.J.S.) has seen it performed by experienced surgeons, performed it himself on cadavers and reached the following conclusions about it, *vis-à-vis* endaural tympanoplasty without flap:

The exponents of CAT claim that a complete view of the tympanic cavity is obtained from the posterior aspect. In actual fact this does not apply in cases with a forward lateral sinus and low dura. It is also stated that the facial nerve is not unduly at risk. Actually it is more vulnerable in CAT than in any other approach.

Much emphasis is laid (in CAT) on a good exposure and clearance of the superior facial recess, but at the same time the *inferior* facial recess (or sinus tympani), which is much larger and deeper, receives very off-hand attention. With ETWOF the former gets adequate exposure, and the latter a better exposure still.

Endaural tympanoplasty without flap

In ETWOF complete access to the epitympanum is obtained, as it is in any other endaural mastoidectomy. A good working view is had of the hypotympanum and of the tubotympanic area. In practice, if cholesteatoma is so widespread as to invade these areas, a radical operation would probably be needed anyway.

The main reason for a CAT is the avoidance of a residual mastoid cavity which would necessitate repeated visits to the surgery for cleaning; yet this of itself is no hazard, whilst the possibility of a hidden accumulation of keratin behind a solid bony wall certainly is. Endaural Tympanoplasty Without Flap eliminates both these possibilities.

A bony partition hides any early deep sepsis or recurrent cholesteatoma and therefore follow-up is life-long. The portion of posterior meatal wall deep to a bony partition is relatively weak and liable to localized retraction and pocket-formation. The retention of a bony portion may therefore be an actual disadvantage in that it prevents the uniform retraction that occurs with ETWOF.

Other advantages of ETWOF are: (i) The preservation of healthy mastoid bone, (ii) the early viewing of the incudostapedial joint (oval window area) and (iii) dispensing with the necessity of a postauricular scar and drain-tube.

There is no doubt that Combined Approach Tympanoplasty is a fascinating operation with a special appeal for the enthusiast. Perhaps therein lies its main danger. Endaural Tympanoplasty Without Flap may be confidently recommended to any otologist with experience of orthodox middle-ear surgery.

With CAT an ossicular reconstruction or the proper positioning of a prosthesis can be controlled *after* the application of a graft. Admittedly, this is not possible with ETWOF. Moreover, reports on the results of CAT are based on thousands of cases. Only thirty-four cases of ETWOF are so far reported (here).

Sheehy (1970) was, with House, one of the pioneers of CAT and is a champion of the Intact (bony) Canal Wall Technique. He states (1970) that in their early cases they preserved the whole membranous canal but only part of the bony canal, and that as a result the skin was eventually sucked in leaving prominent bone, resulting in a cavity. Therefore, he is now in favour of preserving the bony wall complete. Judging by Daggett's cases and now by my own, pocketing is paradoxically avoided by completely removing the bone of the posterior canal wall and leaving the skin, which is then uniformly retracted by clot. In other words, the bony element, being the strongest part of the posterior meatal wall, becomes *ipso facto* the weakest point in the argument for the combined approach operation. The secret of success seems to lie not in having a partially solid posterior meatal wall, but in having a complete wall of uniform consistency, whether bony or soft; and it is easier and safer technically

J. J. Sammut

to do away with the bony wall altogether and preserve the whole of the meatal skin. The argument is supported by results.

Moreover, on Sheehy's own admission (1970) residual disease in 'middle ear and mesotympanum' occurred in the same percentage of cases whatever the method used. Recurrent, as opposed to residual, cholesteatoma, is caused by retraction of skin into attic or facial recess. This cannot occur with the soft-meatus-blood-clot technique.

Results on 22 February 1971

Period of Observation: 1 month to 25 months

Total number of ETWOF's performed:	34, all followed up
Number of cases dry to date:	34
Anatomically normal meatus:	33
Small, healthy, mastoid cavity:	1 (an early case)
Reperforations, dry, in desiccated graft:	2

Hearing	No. cases done	A-B gap closed	A-B gap not closed		
			20 dB gain	15 dB gain	ISQ
Extended Type I	10	8	—	1	1
Type II	5	3	—	—	2
Types III and IV	19	9	3	3	4

Summary and conclusions

When introducing his operation, Daggett says: 'The essential object is to preserve the main part of the meatal soft tissues and to depend upon blood-clot for the total, or at any rate partial, obliteration of dead space in the posterior part of the cavity.' This object seems to have been achieved by the modification described here, which, moreover, benefits, especially for hearing, from the advantages offered by microscopy and the principles of tympanoplasty as laid down later by Wullstein. The method could perhaps be appropriately described as 'the grafting of Wullstein's onto Daggett's operation.' The preservation of the soft meatal wall by no means precludes the use of prosthetics or the reconstruction of the ossicular chain.

The details of the procedure, none of which (as pointed out in the introduction) are original individually, are derived as follows:

- (1) (Indirectly). Schwartze's simple mastoidectomy (1873).
- (2) Bondy's modified radical (1970) for conservatism.
- (3) It reaches all portions of the middle ear—Radical Mastoid (Zaufal, 1890).
- (4) It does not leave an open mastoid cavity—CAT and oblitative techniques. When the author was Harold Kisch's house surgeon back in 1946 he (H.K.) was already turning down temporalis muscle flaps into mastoid cavities.

Endaural tympanoplasty without flap

(5) It relies on blood-clot for obliteration and for maintaining a normal meatus—Daggett's operation.

(6) It employs the use of the binocular operating microscope (Holmgren, 1923).

(7) It uses a low-metabolism tissue for graft—Plester and others.

(8) It protects the round window } Theory of von Helmholtz

(9) It restores the impedance- } (1868), and Tympanoplasty of
matching mechanism } Wullstein.

(10) No more than reasonable risk to facial nerve—important for any ear operation.

(11) It employs the Sterispon 'sausage'—after McGuckin.

(12) It preserves meatal patency—essential requisite for any ear operation.

(13) It does not leave a depressed postauricular scar: aesthetically ideal—Lempert's fenestration and Shambaugh's operation for congenital middle-ear deficiencies, and other endaural approaches.

REFERENCES

- BARON, S. H. (1967) *Archives of Otolaryngology*, **86**, 361.
BONDY, G. (1970) *Monatsschrift für Ohrenheilkunde*, **44**, 15.
DAGGETT, W. I. (1949) *Journal Laryngology and Otology*, **63**, 635.
GUILLON, H., and BATISSE, R. (1963) *Archives of Otolaryngology*, **78**, 759.
VON HELMHOLTZ, H. L. F. (1868) *Pflüger's Archiv für die gesamte Physiologie*, **1**, 1.
HOLMGREN, G. (1923) *Acta Otolaryngologica*, **30**, 1519.
JANSEN, C. (1963) *Laryngoscope*, **73**, 1288.
JUERS, A. L. (1954) *Laryngoscope*, **64**, 3. Quoted by G. E. Shambaugh (1959).
Surgery of the Ear, Philadelphia, p. 413.
KISCH, H. (1946) Personal association.
LEMPERT, J. (1938) *Archives of Otolaryngology*, **28**, 42.
MCGUCKIN, F. (1958) *Journal of Laryngology and Otology*, **72**, 535.
MAWSON, S. (1967) *Diseases of the Ear*, London, p. 503.
PLESTER, D. (1963) Personal conversation, at British Conference in Otorhinolaryngology.
PORTMANN, M. (1963) *Archives of Otolaryngology*, **78**, 2.
PROCTOR, B. (1964) *Journal of Laryngology and Otology*, **78**, 631.
RAMBO, T. (1963) *II Workshop on Reconstructive Middle-ear Surgery*, Chicago, 25 February to 1 March, 1963. Reproduced in *Archives of Otolaryngology*, **70**, 350.
SAMMUT, J. J. (1968) *Journal of Laryngology and Otology*, **82**, 283.
SHAMBAUGH, G. E. (1959) *Surgery of the Ear*. Philadelphia, p. 420.
SHEEHY (1970) *Journal of Laryngology and Otology*, **84**, 1.
STORRS, L. A. (1961) *Archives of Otolaryngology*, **74**, 45.
WULLSTEIN, H. (1953) Die Tympanoplastik gehorverbessernde Operation bei Otitis Media chronica und ihr Resultate. *Proceedings of the Fifth International Congress on Otorhinolaryngology*, p. 104.
ZAUHAL, E. (1890) *Archiv für Ohrenheilkunde*, **30**, 291.
ZOLLNER, F. quoted by G. E. SHAMBAUGH (1959) *Surgery of the Ear*, Philadelphia, p. 413.

Olive Street,
The Gardens, St. Julian's, Malta.

