



An Acute Case of Expressive Aphasia Following Ischaemic Stroke

**External
Reviewer**

Dr. Christian Zammit
M.D.,M.Sc.

Tutor

Dr. Darlene Mercieca Balbi

Mr. D.C. is a 75-year old gentleman brought to casualty after a neighbour found him unable to speak. Since he was severely aphasic, he was unable to give a proper history. The patient was able to understand commands, making this a pure expressive aphasia. He was also noted to have right hemiparesis and right facial weakness. On examination, Mr D.C. was found to have 0/5 power on the right half of his body and 3/5 power on the left side of his body using the MRC muscle power assessment scale. He was noted to have right facial weakness in an upper motor neurone lesion pattern. He was urgently admitted to a medical ward and a CT scan was requested. The scan confirmed a left middle cerebral artery (MCA) ischaemic infarct affecting the basal ganglia and Broca's Area in the inferior frontal lobe.

Fact file on Expressive Aphasia

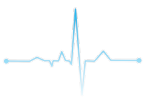Expressive aphasia, also known as Broca's aphasia or non-fluent aphasia, is a condition which is characterized by a loss of the ability to produce both spoken and written language. Although patients are unable to communicate properly, their understanding of speech is mostly intact and much better than when compared to their speech.

The most common cause of Broca's aphasia is a left middle cerebral artery thrombus or embolus causing a stroke which affects the third frontal convolution of the frontal lobe, which is also known as Broca's area (Figure 1), and extending into the white matter. However, it may also be caused by any disease or injury which might

affect Broca's area. The fact that the area of this lesion is anterior to the inferior part of the precentral gyrus, which is responsible for executing voluntary motor movements, explains why there is also associated weakness in the right upper extremity in this condition ("Stroke Rehabilitation: A Function-Based Approach," 2000).

In contrast to Broca's area, Wernicke's area is important in the understanding of speech not the production of speech. Damage to this area of the brain results in impaired comprehension of speech as well as generation of speech which may contain paraphrase and neologisms, often resulting in a word salad. It is located in the sensory area of the posterior superior temporal lobe in the dominant cerebral hemisphere, close to the lateral sulcus. Infarction of the Middle Cerebral Artery can result in both Broca's aphasia and Wernicke's aphasia. The superior division of the middle cerebral artery supplies Broca's area, therefore decreased perfusion of this vessel or more proximal to it will cause Broca's aphasia. Wernicke's area is supplied by the inferior division of the MCA. Strokes of the inferior MCA hence result in Wernicke's aphasia ("Broca's, Wernicke's and Conduction Aphasia," 2006).

Patients suffering from Broca's aphasia have a dominant feature of agrammatism in their speech and thus find it hard to form full sentences even though content words like verbs and nouns are preserved. Patients therefore end up producing speech which is described as



'telegraphic speech'. Patients' ability to repeat words and sentences is also very poor ("Broca's Aphasia," n.d.). There is currently no treatment for aphasia. The approach to facilitating the patient's quality of life is a multidisciplinary approach involving speech therapy, physiotherapy, neurologists and psychologists. Recovery of language function peaks within two to six months, after which progress decreases, however the patient is still encouraged to keep on working on speech production as improvement can be seen long after the stroke (Acharya and Dulebohn, 2017).

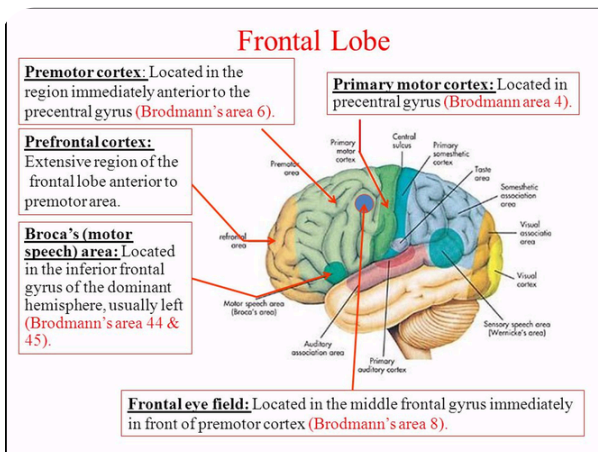


Figure 1 – Diagram illustrating the frontal lobe of the brain and showing Broca's area

This condition is named after Paul Pierre Broca (Figure 2), a French general surgeon who contributed greatly to the field of anatomy. His most important contribution was his discovery of the specific region in the brain that is responsible for speech, Broca's area, in 1861 (Joynt, 1964). Data on the incidence of expressive aphasia is quite limited, however it is estimated that 11,400 people in Britain become aphasic every year following stroke (Wade et al., 1986)



Figure 2 – Portrait of Paul Pierre Broca

Case Report on Acute Expressive Aphasia Following Ischaemic Stroke:

Presenting Complaint:

Mr. DC, a 75-year old male, was found by his neighbour expressively aphasic and suffering from right hemiparesis and right facial weakness. No other symptoms were able to be elicited in the history other than what was clearly visible.

Past Medical/ Surgical History, Family History, Drug History and Social History:

Since the patient was severely aphasic it was not possible to obtain a thorough history from him.

Systemic Inquiry:

Nil of note.

Physical Examination and Preliminary Investigations:

A full neurological examination was carried out.

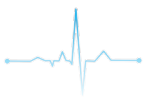On examination:

- Right upper limb power: 0/5 (flaccid)
- Right lower limb power: 0/5
- Right facial nerve palsy with upper motor neuron lesion patterns
- Left upper limb power: 3/5
- Left lower limb power: 3/5

Power was assessed using the MRC power scale (Table 1).

Grade	Description
0	No contraction
1	Flicker or trace of contraction
2	Full range of active movement, with gravity eliminated
3	Active movement against gravity
4	Active movement against gravity and resistance
5	Normal power

Table 1: The MRC score of muscle strength



Further general examinations and investigations were also performed. The following are the findings:

- Chest was clear
- Abdomen was soft and non-tender
- Heart sounds S1 and S2 were intact with no added heart sounds
- Tachycardic with a rate of 115 beats per minute
- Blood pressure was found to be 117/77
- Oxygen saturations: 99% SaO₂
- Afebrile

Various stroke screening techniques were used. The results are shown in the following figures:

Has there been loss of consciousness or syncope? Y (-1) N (0) **UNKNOWN**

Has there been any seizure activity? Y (-1) N (0) **UNKNOWN**

Is there a **NEW ACUTE** onset of any of the following symptoms (or on awakening from sleep)?

1. Asymmetrical facial weakness Y (+1) No (0)
2. Asymmetrical arm weakness Y (+1) No (0)
3. Asymmetrical leg weakness Y (+1) No (0)
4. Speech disturbance Y (+1) No (0)
5. Visual field defect Y (+1) No (0)

* Total Score 4 (-2 to +5)

Stroke is likely if total scores are >0. Scores of <= 0 have a low possibility of stroke but not completely excluded.

Provisional diagnosis Stroke None stroke (specify) _____

- If total score > 0 (1-6) a diagnosis of acute stroke is likely, refer to NGH stroke ED guidelines and bleep stroke team on 2939 for transfer to the stroke service at RHH (if under 4½ hours since stroke onset, contact stroke team immediately for consideration for thrombolysis)
- If total scores 0, -1 or -2 stroke unlikely but is not totally excluded, bleep stroke team on 2939 for advice.

Figure 3: Rosier (Recognition of Stroke in the Emergency Room) Score

Category	Score/Description	Date/Time Initials	Date/Time Initials	Date/Time Initials	Date/Time Initials	Date/Time Initials
1a. Level of Consciousness (Alert, drowsy, etc.)	0 = Alert 1 = Drowsy 2 = Stuporous 3 = Coma	0				
1b. LOC Questions (Month, age)	0 = Answers both correctly 1 = Answers one correctly 2 = Incorrect	/				
1c. LOC Commands (Open/close eyes, make fist/clap)	0 = Obeys both correctly 1 = Obeys one correctly 2 = Incorrect	0				
2. Best Gaze (Eyes open - patient follows examiner's finger or face)	0 = Normal 1 = Partial gaze palsy 2 = Forced deviation	0				
3. Visual Fields (Introduce visual stimulus/threat to pt's visual field quadrants)	0 = No visual loss 1 = Partial Hemianopia 2 = Complete Hemianopia 3 = Bilateral Hemianopia (Blind)	0				
4. Facial Paresis (Slowly raise eyebrows and squeeze eyes shut)	0 = Normal 1 = Minor 2 = Partial 3 = Complete	1				
5a. Motor Arm - Left	0 = No drift 1 = Drift 2 = Can't resist gravity 3 = No effort against gravity	Left 0				
5b. Motor Arm - Right (Elevate arm to 90° if patient is sitting, 45° if supine)	0 = No movement 1 = Unstable (Joint fusion or limb amp)	Right 4				
6a. Motor Leg - Left	0 = No drift 1 = Drift 2 = Can't resist gravity 3 = No effort against gravity	Left 0				
6b. Motor Leg - Right (Elevate leg 30° with patient supine)	0 = No movement 1 = Unstable (Joint fusion or limb amp)	Right 2				
7. Limb Ataxia (Finger-nose, heel-down shin)	0 = No ataxia 1 = Present in one limb 2 = Present in two limbs	/				
8. Sensory (Pin prick to face, arm, trunk, and leg - compare side to side)	0 = Normal 1 = Partial loss 2 = Severe loss	/				
9. Best Language (Name item, describe a picture and read sentences)	0 = No aphasia 1 = Mild to moderate aphasia 2 = Severe aphasia 3 = Mute	2				
10. Dysarthria (Evaluate speech clarity by patient repeating listed words)	0 = Normal articulation 1 = Mild to moderate slurring of words 2 = Near to unintelligible or worse 3 = Inarticulate or other physical barrier	2				
11. Extinction and Inattention (Use information from prior testing to identify neglect or double simultaneous stimuli testing)	0 = No neglect 1 = Partial neglect 2 = Complete neglect	0				
TOTAL SCORE		11/42				

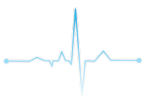Figure 4: NIH (National Institutes of Health) Stroke Score

NIHSS SCORE	STROKE SEVERITY	IMPACTED BRAIN DENSITY
0	No Stroke	
0 - 4	Minor Stroke	
5 - 15	Moderate Stroke	
16 - 20	Moderate to Severe Stroke	
21 - 42	Severe Stroke	

Figure 5: NIH Stroke Scale Interpretation

Investigations ordered:

1. ECG – To identify any predisposing conditions which may have resulted in the stroke e.g.: Atrial fibrillation/flutter, acute myocardial infarction, infective endocarditis etc. In case any are identified, further prophylactic treatment may be indicated.
2. Routine bloods (Complete Blood Count, ESR, CRP, Urea and Electrolytes, Blood Glucose Levels etc) – to rule out underlying conditions such as sepsis, renal disease and diabetes. Inflammatory markers are often raised in ischaemic stroke. In case any are identified, further treatment may be indicated.
3. CT brain – To determine whether the stroke was ischaemic or haemorrhagic in nature, to properly locate the lesion and to rule out any possible differentials such as space occupying lesions.
4. Echocardiogram – To rule out any underlying structural heart disease which may have caused the stroke e.g.: Valvular heart disease, patent foramen ovale, atrial septal aneurysm etc. In case any are identified further prophylactic treatment may be indicated.
5. Carotid doppler ultrasound – To identify any possible stenosis or plaque build-up in the carotid arteries which may predispose to recurrent strokes. If stenosis is greater than 50%, carotid endarterectomy may be indicated.
6. Geriatric review
7. Stroke rehabilitation including outreach to physiotherapy, occupational therapy and



speech therapy – Stroke management is a multidisciplinary effort.

Findings:

- The CT brain revealed an ischaemic stroke of the middle cerebral artery territory. CT brain results are shown below:

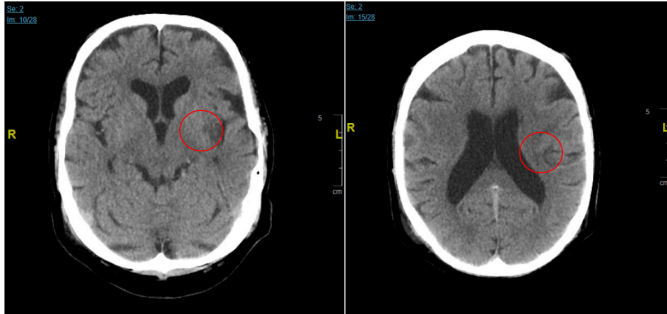


Figure 6: Mr. DC's Brain CT demonstrating areas of ischaemic infarction in the left Middle Cerebral Artery territory

- Mr DC's ECG revealed atrial flutter, a possible source of emboli which may have resulted in the stroke.
- C-Reactive Protein was found to be 51.9 mg/L (normal range <3.0 mg/L). This is common in stroke patients since acute ischaemic stroke may trigger an inflammatory response in the surrounding tissues.
- No abnormalities seen on the echocardiogram.
- Carotid doppler showed no stenosis or atherosclerosis of the carotid arteries.
- Carotid doppler results are shown below:

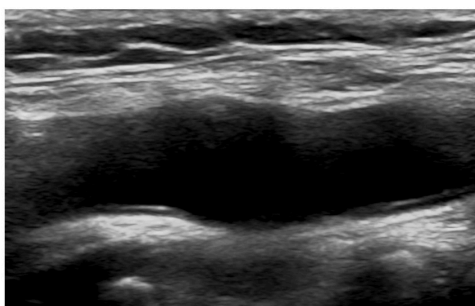


Figure 7: Mr. DC's Carotid Doppler showing a patent carotid artery with no signs of stenosis or atherosclerotic plaque

Right			
	CCA	ICA	ECA
PSV	92	92	65
EDV	12	33	10
ICA/CCA	N/A		
% stenosis	N/A	N/A	N/A
SMR	N/A		
Vertebral			
PSV	65		
Direction	Antegrade		
Remarks			
The visualised carotid arteries are patent with no evidence of atherosclerotic plaque or stenosis.			
Dimitrie Cassar Vascular Lab Green Island, Mater Dei Hospital			
Left			
	CCA	ICA	ECA
PSV	94	97	73
EDV	17	31	10
ICA/CCA	N/A		
% stenosis	N/A	N/A	N/A
SMR	N/A		
Vertebral			
PSV	43		
Direction	Antegrade		

Figure 8: Mr. DC's Carotid Doppler results

Pharmacological Therapy:

Since the CT showed that the stroke was ischaemic rather than haemorrhagic, pharmacological intervention was indicated rather than a surgical approach.

The patient was outside the therapeutic window for administration of Tissue plasminogen activator (tPA) which is 3-4.5 hours, and was therefore started on aspirin 75mg daily, Dipyridamole 100mg tds and Simvastatin 20mg daily. The patient was also started on omeprazole 20mg once daily due to the potential side effect of gastrointestinal bleeding associated with aspirin.

The antiplatelet (Dipyridamole) is to be switched to warfarin after 4-6 weeks. 4 weeks are allowed before switching in order to prevent haemorrhagic conversion i.e. the transformation of an ischaemic stroke into a haemorrhagic stroke. Mr DC was also started on Perindopril 2mg once daily.

Follow Up:

Mr. DC was monitored and followed up closely during the week he spent at Mater Dei Hospital recovering from the stroke. The following is a summary of his recovery:

Day 1 Post Stroke:



- Patient aphasic but able to communicate with hand gestures and by writing on paper
 - Patient found to have good gait pattern
 - No dyspraxia
- Right sided facial weakness persistent but able to swallow.

Day 2 Post Stroke:

- Blood pressure increased to 120/80
- IVI stopped and cannula removed

Day 3 Post Stroke:

- Patient noted to have increased vocabulary – vocalised “thank you”
- Range of movement of the right upper limb noted to have increased substantially
- Able to mobilize with minimal help
- Activities of daily living require help

Day 4 Post Stroke:

- Ambulation and balance good
- Improvement in speech - “I don’t like it”
- Hot cold sensation intact
- Communication impairment prevented full interpretation of sensory testing

Day 5 Post Stroke:

- Patient managing to carry out all activities of daily living independently
- Only remaining issue is speech but it is improving, according to wife
- Good gait and balance

Day 6 Post Stroke:


- Upper limb sensory testing repeated - patient noted to have decreased sensation mostly in sharp/dull discrimination. Patient was able to identify light touch
- Able to form sentences but speech intelligibility remains poor
- Written word only contains minor spelling errors which were self-corrected

Day 7 Post Stroke:

- No further physiotherapy or speech therapy needed
- Patient to be discharged home to be supported by wife

References:

1. Acharya, A.B., Dulebohn, S.C., 2017. Aphasia, Broca, StatPearls.
2. Broca's Aphasia [WWW Document], n.d. URL <https://www.asha.org/Glossary/Brocas-Aphasia/>
3. Joynnt, R.J., 1964. Paul Pierre Broca: His Contribution to the Knowledge of Aphasia. Cortex. [https://doi.org/10.1016/S0010-9452\(64\)80022-8](https://doi.org/10.1016/S0010-9452(64)80022-8)
4. Broca's, Wernicke's and Conduction Aphasias [WWW Document], 2006. . Case West. Reserv. Univ. Sch. Med. URL <http://casemed.case.edu/clerkships/neurology/NeurLrngObjectives/Brocas.htm>
5. Stroke Rehabilitation: A Function-Based Approach, 2000. . Am. J. Occup. Ther. <https://doi.org/10.5014/ajot.54.3.349>
6. Wade, D.T., Hewer, R.L., David, R.M., Enderby, P., 1986. Aphasia after stroke: Natural history and associated deficits. J. Neurol. Neurosurg. Psychiatry. <https://doi.org/10.1136/jnnp.49.1.11>



Hannah Xuereb
4th Year Medical Student at the Faculty of Medicine & Surgery, University of Malta.



Adam Al Gedei
4th Year Medical Student at the Faculty of Medicine & Surgery, University of Malta.