

## Retropharyngeal abscess with atlanto-axial subluxation

Veronica Said-Pullicino, Andre Stefan Gatt, David Pace

We describe a case of a 4-year-old boy who presented with fever, neck pain and bilateral non-suppurative cervical lymphadenopathy. Torticollis, painful limitation of neck movements and nuchal tenderness were present. CT scan revealed a retropharyngeal abscess and rotatory subluxation of the atlanto-axial joint, consistent with Grisel's syndrome. This is an important differential in children with fever and torticollis as if unrecognized, may potentially lead to serious neurological deficits from cervical cord compression.

**Veronica Said-Pullicino\***

MD, MRCPCH  
Higher Specialist Trainee  
Department of Child & Adolescent  
Health,  
Mater Dei Hospital,  
Msida, Malta  
[veronica.said-pullicino@gov.mt](mailto:veronica.said-pullicino@gov.mt)

**Andre Stefan Gatt**

MD, MRCS, FRCR  
Consultant Pediatric Radiologist  
Mater Dei Hospital,  
Msida, Malta

**David Pace**

MD, Pg Dip PID (Oxf), FRCPCH, PhD  
Consultant Infectious Disease  
Pediatrician  
Postgraduate Training Coordinator in  
Pediatrics and Neonatology  
Mater Dei Hospital,  
Msida, Malta

\*Corresponding author

The Editorial Board retains the copyright of all material published in the Malta Medical School Gazette. Any reprint in any form of any part will require permission from the Editorial Board. Material submitted to the Editorial Board will not be returned, unless specifically requested.

---

### CASE REPORT

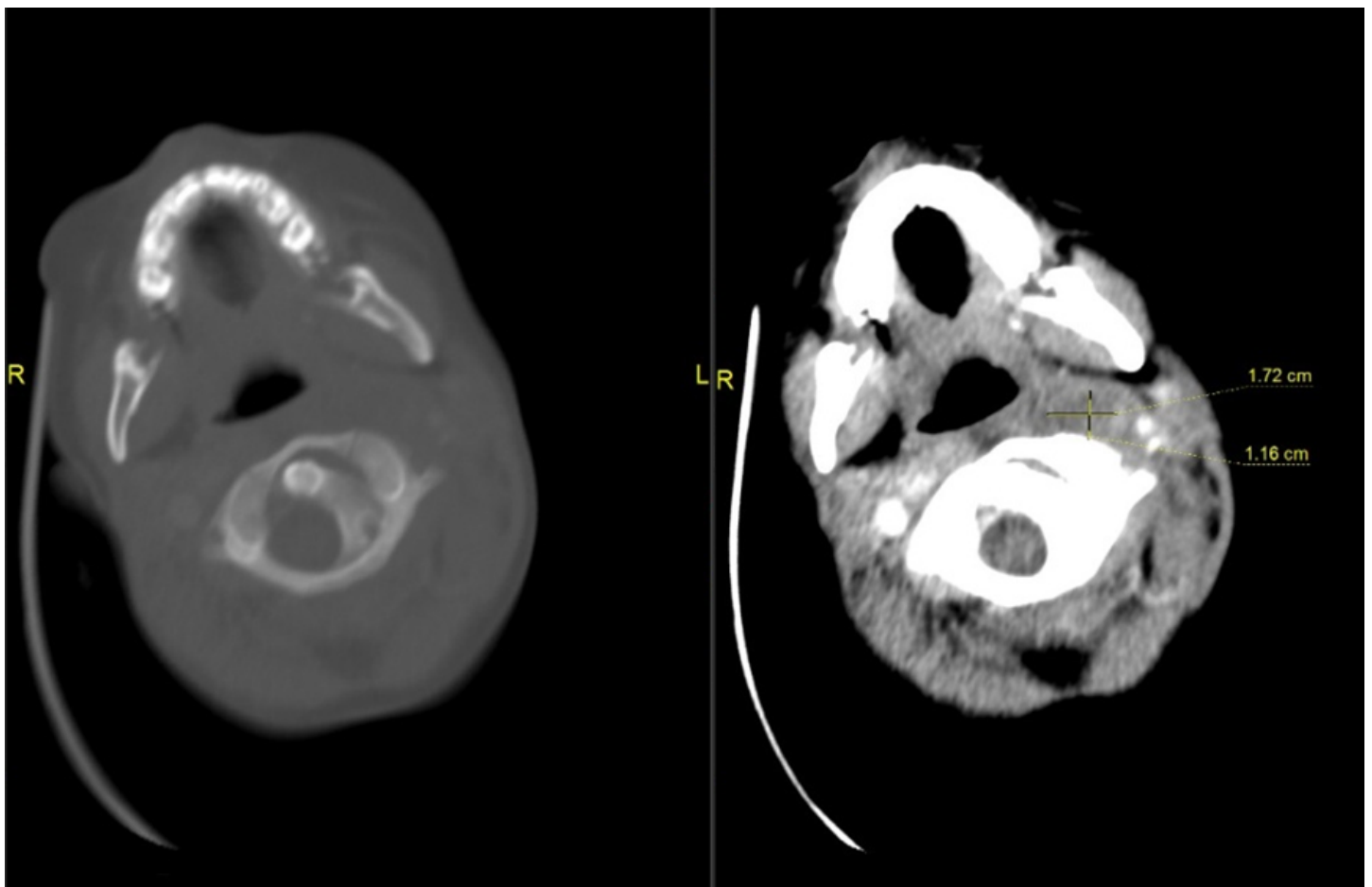
---

A 4-year old Caucasian boy with no significant past medical history, who was on holiday in Malta, was referred for evaluation of a 1 week history of cough and rhinorrhea followed by 8 hours of fever of up to 38.2°C, neck pain and odynophagia that limited his oral intake. There was no history of vomiting, photophobia, rashes or trauma to the neck. On examination, the child looked generally well and was not lethargic. He had a temperature of 38.2°C, a

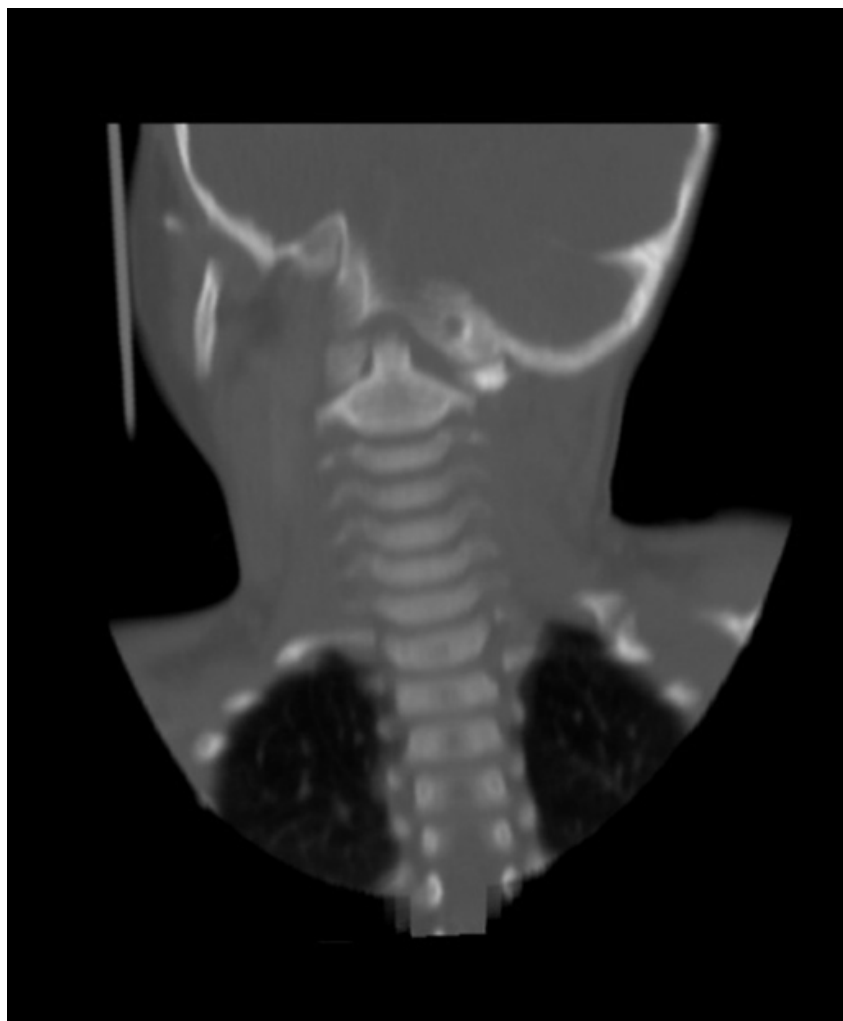heart rate of 135 beats/minute, was normotensive, not tachypnoeic and had satisfactory oxygen saturations in air. He had bilateral non-suppurative cervical lymphadenopathy with torticollis to the right, together with painful limitation of neck movements and nuchal tenderness. Mouth opening was significantly limited due to pain. There was no drooling or stridor, and no neurological deficit was present. ENT examination revealed pharyngitis with no pus or membrane.

---

**Figure 1** CT scan in bone window: rotatory subluxation of the atlanto-axial joint – the left lateral facet of C1 is anteriorly displaced relative to its corresponding facet on C2. The soft tissue window demonstrates the poorly enhancing inflammatory phlegmon (1.7cm x 1.2cm) in the left retropharyngeal space.



**Figure 2** Coronal CT scan in bone window demonstrates marked asymmetry of the lateral masses of C1 relative to C2 and the remainder of the cervical spine.



He was initially started on maintenance intravenous fluids due to decreased oral intake, together with analgesia as required. Notable laboratory results included an elevated neutrophil count of  $18.3 \times 10^9/L$  and a C-reactive protein that reached 241mg/L. Blood cultures were negative. An ultrasound of the neck showed multiple prominent lymph nodes in the left submandibular region and along the left cervical chain, the largest measuring 8mm in short axis dimension, together with increased internal vascularity in keeping with inflammatory changes. The thyroid, parotid and submandibular glands were normal. In view of persistent fever, torticollis and raised inflammatory markers, a

computed tomography (CT) scan of the neck was performed and this revealed a left - sided retropharyngeal abscess measuring 1.7cm x 1.2cm, with an associated rotatory subluxation of the atlanto-axial joint (Figure 1 and 2) consistent with Grisel's syndrome. Surgical drainage was not required due to clinical improvements. His C-reactive protein and temperature normalised on intravenous cefotaxime and clindamycin and his neck movements improved. No interventions on the cervical spine were necessary since the atlas was not significantly shifted anteriorly. After 10 days of intravenous antibiotics he was discharged and was advised to use a soft collar as he was flying back home.

Recovery was uneventful following a further 2 weeks of high dose oral co-amoxiclav. The torticollis resolved within one month and there was full range of cervical movements. Follow up ultrasound scans of his neck showed resolution of the inflammatory changes.

---

## DISCUSSION

---

A retropharyngeal abscess is a deep infection that forms in a potential space between fascial layers posterior to the pharynx. It is an uncommon but serious infection that presents mostly in the pediatric population. It should be considered in children presenting with neck pain and restricted neck movements, fever, cervical lymphadenopathy, odynophagia and dysphagia. Neck swelling may also be present. Despite the life-threatening airway compromise that may result from respiratory distress and stridor, these are rarely the presenting features.<sup>1-2</sup> Infections of the head and neck may lead to lymphadenitis, cellulitis and eventually suppurative adenitis of the retropharyngeal lymph nodes with abscess formation.<sup>3</sup>

Retropharyngeal abscess is often a polymicrobial infection. Predominant bacterial species responsible are *Streptococcus pyogenes* (Group A streptococcus), *Staphylococcus aureus* including methicillin-resistant *S. aureus* (MRSA), *Haemophilus influenzae* and oral anaerobes. A beta-lactamase-resistant penicillin together with an agent having anaerobic cover will provide appropriate antibiotic cover. Early commencement of appropriate high dose systemic antimicrobial treatment may stop the progression of mature abscess formation from cellulitis or from an organised phlegmon.<sup>2,4</sup> Most patients with a retropharyngeal abscess generally respond to a course of appropriate intravenous antibiotics

and do not require any surgical intervention.<sup>1</sup> McClay et al. describe how 91% of the pediatric patients in their study who had radiographic evidence of a deep neck abscess and had no severe symptoms, responded to intravenous antimicrobial treatment alone.<sup>5</sup>

Prompt diagnosis and treatment of retropharyngeal abscesses is imperative so as to avoid complications that may be potentially fatal. Infection may spread to the bloodstream, to other deep neck spaces or to adjacent structures, leading to mediastinitis, aspiration pneumonia if the abscess ruptures into the airway and internal jugular vein thrombosis amongst others.<sup>6</sup>

Rarely a retropharyngeal abscess may be associated with non-traumatic fixed rotary atlanto-axial subluxation, a condition known as Grisel's syndrome. This should be suspected if there is concurrent torticollis with neck stiffness and possibly pain on neck movement, in a child with a history of fever with recent infection or surgery in the head and neck.<sup>7</sup>

Atlanto-axial subluxation refers to a loss of stability between the atlas (C1) and axis (C2). This results in abnormal articulation between the vertebrae and may progress to dislocation. The presentation may range from minor axial neck pain to death. Approximately 50% of patients present with restricted neck movements and/or neck pain, 70% with numbness and/or weakness and 90% with pyramidal signs. They may also present with sphincter disturbances, lower cranial nerve pathology and respiratory compromise.<sup>8</sup>

Grisel's syndrome commonly affects children, with 68% of cases occurring in those under 12 years of age and 90% occurring in those under 21 years of age. Radiological evaluation with CT scan of the neck is the gold standard for diagnosis of Grisel's syndrome. An increased

atlanto-odontoid distance (>5mm in children) may be found in lateral projections.<sup>9-10</sup>

The etiology is uncertain and though several theories have been proposed to explain the pathogenesis of the inflammatory subluxation, this continues to be debated.<sup>9</sup> The two-hit hypothesis proposed by Battiatà and Pazos (2004) gives a hypothetical explanation for the aetiology. It states that atlanto-axial subluxation results from a pre-existing cervical ligamentous laxity, seen commonly in the pediatric population, worsened by inflammatory mediators from the retropharyngeal space that are transported to the soft tissues of the atlanto-axial space via the pharyngovertebral plexus, that lead to cervical muscle spasm.<sup>9-10</sup> Although the etiopathogenesis of Grisel's syndrome has not been proven, a history of pharyngitis, adenotonsillitis, peritonsillar abscess, otitis media, upper respiratory tract infection, certain genetic disorders and head and neck surgery have been reported as risk factors.

Many acute cases can be treated conservatively with bed rest, antimicrobials, anti-inflammatory agents, immobilization and may also require simple traction, however some acute cases and most of the chronic cases with symptoms persisting more than one month, require surgical intervention. This may include skeletal traction or bone fusion. In pediatrics, whenever possible, conservative treatment is preferred.<sup>7</sup>

---

### CONCLUSION

---

Grisel's syndrome is an uncommon but important differential in children with fever and torticollis. Prognosis highly depends on early intervention as delay in diagnosis may be dramatic. Clinicians should be aware of acute non-traumatic torticollis after recent head and neck surgery or recent local infection, as, if unrecognized, it may potentially progress and lead to painful and long-lasting deformity of the neck or serious neurological deficits from cervical cord compression, including death.<sup>7,9</sup>

---

### REFERENCES

---

1. Grisarù-Soen G, Komisar O, Aizenstein O, Soudack M, Schwartz D, Paret G. Retropharyngeal and parapharyngeal abscess in children - epidemiology, clinical features and treatment. *Int J Pediatr Otorhinolaryngol.* 2010;74(9):1016-20.
2. Tebruegge M, Curtis N. Infections related to the upper and middle airways. In: Long SS, Pickering LK, Prober CG, editors. *Principles and Practice of Pediatric Infectious Diseases.* 3rd ed. New York: Elsevier Saunders; 2012. p.205.
3. Goldstein NA, Hammerslag MR. Peritonsillar, retropharyngeal, and parapharyngeal abscesses. In: Feigin RD, Cherry JD, Demmler-Harrison GJ, Kaplan SL, editors. *Textbook of Pediatric Infectious Disease.* 6th ed. Philadelphia: Elsevier Saunders; 2009. p.177.
4. Brook I. Microbiology and management of peritonsillar, retropharyngeal, and parapharyngeal abscesses. *J Oral Maxillofac Surg.* 2004;62(12):1545.
5. McClay JE, Murray AD, Booth T. Intravenous Antibiotic Therapy for Deep Neck Abscesses Defined by Computed Tomography. *Arch Otolaryngol Head Neck Surg.* 2003;129(11):1207-1212.
6. Yellon RF. Head and neck space infections. In: Bluestone CD, Simons JP, Healy GB, editors. *Pediatric Otolaryngology.* 5th ed. Philadelphia: Elsevier Saunders; 2014. p.1769.

7. Bucak A, Ulu S, Aycicek A, Kacar E, Miman MC. Grisel's Syndrome: A Rare Complication following Adenotonsillectomy. *Case Reports in Otolaryngology*. vol. 2014, Article ID 703021, 4 pages. [Internet]. 2014 [cited 5th January 2018]. Available from: <https://doi.org/10.1155/2014/703021>.
8. Yang SY, Boniello AJ, Poorman CE, Chang AL, Wang S, Passias PG. A Review of the Diagnosis and Treatment of Atlantoaxial Dislocations. *Global Spine J*. 2014;4:197–210.
9. Lee SH. Grisel Syndrome: Pathophysiological Evidence from Magnetic Resonance Imaging Findings. *Ann Rehabil Med*. 2013;37(5):713-6.
10. Battiata AP, Pazos G. Grisel's syndrome: the two-hit hypothesis-a case report and literature review. *Ear Nose Throat J*. 2004;83:553-5.