

# **CORONARY ARTERY SPASM: ROLE IN ACUTE MYOCARDIAL ISCHAEMIA**

*ROBERT G. XUEREB M.D., M.R.C.P. (UK)  
MARIOS A XUEREB M.D., M.R.C.P. (UK)*

*DEPARTMENT OF CARDIOLOGY  
ISTITUTO SCIENTIFICO H SAN RAFFAELE, MILAN, ITALY.*

*Address for correspondence: Robert G. Xuereb MD, MRCP (UK), Department of Cardiology,  
Istituto Scientifico H San Raffaele, Via Olgettina 60, 20132, Milano, Italy.*

## **INTRODUCTION**

Coronary artery spasm is an accepted cause of transient myocardial ischaemia in patients with variant angina. Guazzi et al<sup>1</sup> and Maseri et al<sup>2</sup> have clearly demonstrated that in these patients angina is not preceded by increased myocardial metabolic demand. The electrocardiographic abnormality, ST segment elevation, which is a hallmark of this syndrome, resembles that seen experimentally when the animal coronary artery is ligated and clinically, when the human coronary artery is totally occluded by a balloon angioplasty catheter. Chierchia et al<sup>3</sup> assessed continuous coronary sinus oxygen content and showed a decrease in coronary sinus oxygen preceding

both electrocardiographic changes and chest pain, providing the first demonstration that a primary reduction in blood supply is indeed responsible for ischaemia in these patients.

More recently, coronary artery spasm has also been suggested to play an important role in the pathophysiology of myocardial ischaemia throughout the wide clinical spectrum of coronary artery disease including effort angina, unstable angina, acute myocardial infarction and sudden death.<sup>4</sup>

## **DEFINITION**

Coronary artery spasm is defined as a severe localized constriction sufficiently profound to cause transient total or sub-total occlusion of an epicardial

coronary artery resulting in myocardial ischaemia. Dynamic lumen obstruction is often observed in the proximal trunk or trunks, and the right coronary artery is most often involved. In some cases, spasm may be multifocal or diffuse. It may occur in angiographically normal coronary arteries but is usually associated with a localized atheroma (often subtle) or endothelial disruption or dysfunction.

## **CHANGING FASHIONS**

Originally, coronary artery spasm was considered the main mechanism of angina pectoris. Following the recognition of fixed atherosclerotic narrowing in association with angina, this concept fell into disrepute. Wilson and

Johnston<sup>5</sup> reposed the hypothesis of coronary artery spasm in 1941 when they described the occurrence of transient ST segment elevation during an episode of chest discomfort in a patient whilst smoking a cigarette. The entire syndrome of variant angina, an unusual form of angina that occurs exclusively at rest, was described by Prinzmetal et al<sup>6</sup> in 1959. Following these original descriptions, the term coronary artery spasm passed through another unpopular phase in the early 1970's until it became a "proven hypothesis".<sup>7</sup> The last few years have seen a revival in the interest in coronary artery spasm with the publication of numerous important papers on its pathogenesis.

### **PATHOGENESIS: AN EVOLVING PICTURE**

No single cause for coronary artery spasm has been found. Basic as well as clinical investigations indicate that the disorder may be the result of multiple pathophysiological mechanisms.

#### *GENETIC FACTORS*

There have been few reports pertaining to genetic factors in coronary artery spasm. Numano et al<sup>8</sup> found a significantly low frequency of human leucocyte antigen DQw3 as well as a high frequency of Bw52 in 45 Japanese patients with variant angina as compared with 152 normal Japanese adults. These data suggest that some genetic factor or factors may contribute to the pathogenesis of coronary artery spasm.

#### *AUTONOMIC NERVOUS SYSTEM*

**Sympathetic nervous system:** Following the demonstration that stimulation of alpha-adrenergic receptors with epinephrine can cause spasm,<sup>9</sup> altered adrenergic activity has been suggested to play a role in variant angina. However, Chierchia et al<sup>10</sup> analysed the Holter electrocardiogram in 8 patients with variant angina and failed to reveal any increase in heart rate and corrected QT interval (both indices of cardiac sympathetic activation) in the period preceding the onset of ST segment

changes. They also showed that the frequency of ischaemic episodes was not altered by the infusion of the non-selective alpha-blocker phentolamine. Also, specific alpha<sub>1</sub>-receptor blockade by prazosin exerted no obvious beneficial effects.<sup>11</sup> These observations suggest an insignificant role for adrenergic activation in the precipitation of coronary artery spasm.

**Parasympathetic nervous system:** A number of studies have demonstrated that intracoronary infusion of the parasympathetic neurotransmitter acetylcholine in patients with variant angina provokes spasm. In one such study, Yasue et al<sup>12</sup> induced spasm in 25 out of 28 patients. However, these studies have to be interpreted with caution as the pharmacological doses of intracoronary acetylcholine used do not represent the normal physiological condition of parasympathetic stimulation. Furthermore, following the observation that coronary artery spasm can also occur in the denervated transplanted human heart,<sup>13</sup> a primary neural origin seems unlikely.

#### *ROLE OF PLATELETS*

Aggregation of platelets results in the release of several vasoactive substances including thromboxane A<sub>2</sub> and serotonin.

**Thromboxane A<sub>2</sub> - Prostacyclin imbalance:** Chierchia et al<sup>14</sup> showed that inhibition of the potent vasoconstrictor thromboxane A<sub>2</sub> by the administration of a single intravenous low dose of aspirin (2mg/kg) had no obvious clinical effect and the frequency, severity and duration of electrocardiographically documented ischaemic episodes remained practically unchanged. Although the simultaneous suppression of coronary prostacyclin (PGI<sub>2</sub>) synthesis might have contributed to these largely negative findings, this possibility was shown to be unlikely by Chierchia et al<sup>15</sup> in a study using intravenous infusion of antiaggregatory and vasodilator doses of synthetic PGI<sub>2</sub>, where coronary vasospasm was not prevented in 8 of 9 patients with variant angina.

**Serotonin:** Recently there has been increasing interest in the role of serotonin. McFadden et al<sup>16</sup> induced occlusive coronary artery spasm by serotonin in 5 patients with variant angina at a dose that dilates normal vessels. This effect is not prevented by intravenous ketanserin, a 5-HT<sub>2</sub> receptor blocker.<sup>17</sup>

#### *EFFECT OF HISTAMINE*

A recent post-mortem study<sup>18</sup> of a patient with variant angina suffering sudden death demonstrated a significant increase in the number of mast cells in the coronary artery adventitia. It was suggested that histamine or other vasoactive substances are important mediators in the genesis of spasm. Okumara et al<sup>19</sup> induced coronary spasm by intracoronary injection of histamine through stimulation of H<sub>1</sub> receptors.

#### *ENDOTHELIAL DYSFUNCTION*

Since Furchgott's<sup>20</sup> discovery of an endothelium-derived relaxing factor (EDRF), later shown to be probably nitric oxide, the endothelium has been shown to play a pivotal role in the control of coronary arterial tone of epicardial and resistive vessels. EDRF promotes underlying smooth muscle relaxation and vasodilation in response to various agonists, such as acetylcholine, histamine and serotonin, that would cause smooth muscle contraction and vasoconstriction when in direct contact with smooth muscle. It has been suggested that disrupted or dysfunctional endothelium, as well as atherosclerosis, may prevent coronary vasodilation mediated by EDRF, and may be important in the genesis of coronary artery spasm. However, we have recently shown that atheroma and acute intimal injury induced by percutaneous transluminal coronary angioplasty do not influence the endothelial-dependent vasodilation induced by low dose intracoronary acetylcholine,<sup>21</sup> suggesting that an alteration of the local endothelial lining is unlikely to be the primary cause of coronary artery spasm.

## LOCALIZED SMOOTH MUSCLE HYPERREACTIVITY

A recent hypothesis proposed for the genesis of coronary artery spasm is the presence of a hyperreactive coronary smooth muscle segment.<sup>22</sup> The nature of the local coronary alteration that makes a particular coronary segment hyperreactive to constrictor stimuli is not known.

### EFFECT OF COCAINE

Cocaine users frequently develop silent myocardial ischaemia, especially during withdrawal, which is probably caused by cocaine-induced coronary spasm mediated by alpha-adrenergic stimulation. Nademanee et al<sup>23</sup> studied 21 consecutive long-term male cocaine users. 38% had frequent episodes of ST elevation on 24-hour ambulatory electrocardiographic monitoring.

From the above studies it can be concluded that a large number of different stimuli, and not a specific stimulus only, can provoke coronary artery spasm. Kaski et al<sup>22</sup> showed that during spontaneous spasm in six patients with variant angina, the spastic segments had an average reduction in luminal calibre of 64%, whereas all unrelated vessels examined constricted by an average of only 12%. Thus spontaneous local coronary spasm is likely to result from a local exaggerated coronary constrictor response to a variety of stimuli acting on different receptors that produce only mild constriction in other coronary segments and which may be different in different patients and even in the same patient at different times.

## CLINICAL MANIFESTATIONS

The symptoms of patients with coronary artery spasm depend upon the underlying ischaemic clinical syndrome. Classically, they present with recurrent rest pain associated with reversible ST segment elevation and preservation of exercise capacity. This syndrome is termed Prinzmetal's or variant angina. The pain is usually more

severe and of longer duration than that observed in effort angina. Attacks tend to be clustered between midnight and 6 a.m., awakening the patient in the very early morning at nearly the same time. This is important both diagnostically and in the planning of drug therapy since adequate cover is needed particularly during these critical hours. Spontaneous remissions and exacerbations are typical of the syndrome. Up to 90% of ischaemic episodes caused by coronary artery spasm are silent. Patients with Prinzmetal's angina tend to be younger than those with classic stable effort-induced angina. The male preponderance is also less evident. Episodes of spasm may be precipitated by emotional stress and smoking.

Coronary artery spasm may also play a role in patients with effort angina who exhibit a highly variable threshold for the induction of ischaemia, experience walk-through angina, demonstrate ST segment elevation associated with effort or an excellent response to calcium channel blockers and a poor response to beta-blockers.

Unstable angina results from an abrupt alteration in blood supply caused by a complex interaction of plaque fissuring, thrombosis and spasm. Coronary artery spasm is especially likely in those patients who demonstrate ST segment elevation during episodes of chest pain and an absence of increase in the indices of myocardial oxygen demand prior to the onset of pain.

Although a relatively rare complication of variant angina,<sup>4</sup> acute myocardial infarction has been shown to occur in the area supplied by vessels which undergo spasm during transient ischaemic episodes.<sup>24</sup> Hackett et al<sup>25</sup> demonstrated that intracoronary nitrates during the early phase of acute myocardial infarction reverse the intermittent coronary occlusion which is frequently observed during coronary angiography despite thrombolytic therapy.

Following the relief of temporary coronary occlusion due to spasm, life-threatening reperfusion arrhythmias may occur. These may present with

lightheadedness, palpitations, syncope or sudden death.

## RECOGNITION OF CORONARY ARTERY SPASM

### Electrocardiogram

Although transient ST segment elevation is the hallmark of coronary artery spasm, other ischaemic-type ECG changes may occur. These include ST segment depression, T wave inversion, T wave peaking, pseudonormalization of the T wave, inversion of U waves, as well as transient appearance of abnormal Q waves. The changes may occur in any lead but are more common in the inferior leads reflecting the higher frequency of spasm occurring in the right coronary artery. Rhythm disturbances including AV block and ventricular tachycardia may be the only manifestations. Twenty-four hour ECG Holter monitoring is useful for the documentation of both symptomatic and silent ischaemic episodes (Figure 1) as well as for the assessment of the efficacy of drug treatment.

### Exercise Stress Testing

The sensitivity for detecting spasm in patients with variant angina by exercise testing is quite low. ST segment elevation is observed in 30% of patients, ST depression in 30% and no changes in 40%. However the finding of ST elevation is specific for coronary artery spasm only when a previous myocardial infarction has been ruled out.

### Echocardiography

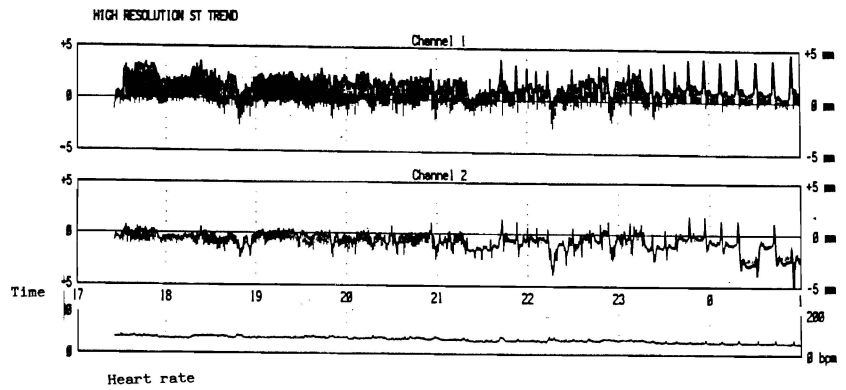
New transient segmental wall motion abnormalities may be observed during spontaneous or provoked spasm.

### Myocardial Perfusion Scintigraphy

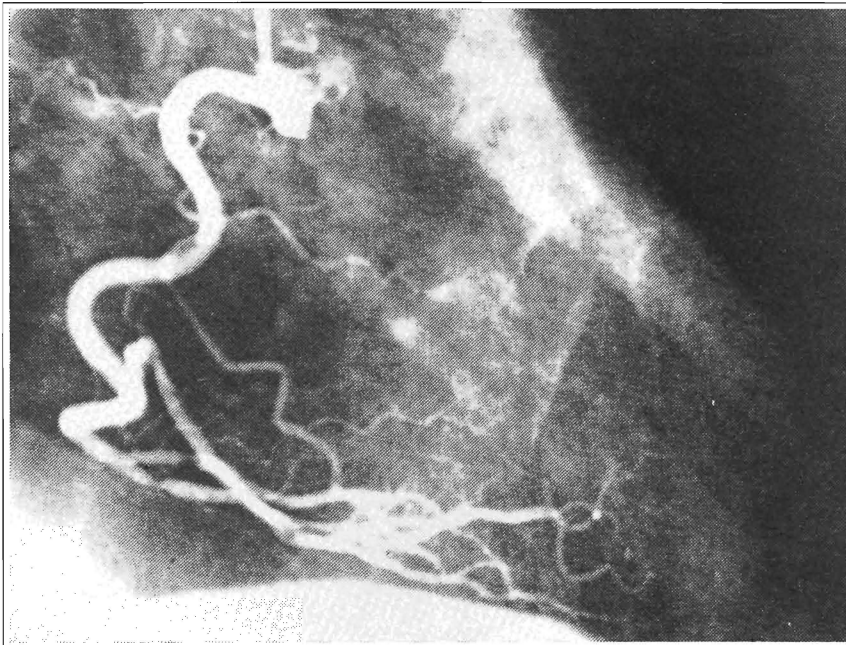
Thallium-201 scintigraphic studies performed during attacks of coronary artery spasm demonstrate regional transmural myocardial perfusion defects corresponding well with leads involved by ST segment elevation.

Legends for figures

Figure 1. High resolution ST trend during 24-hour ECG monitoring in a patient with variant angina showing numerous episodes of transient ST segment elevation without preceding increase in heart rate.



2a



2b

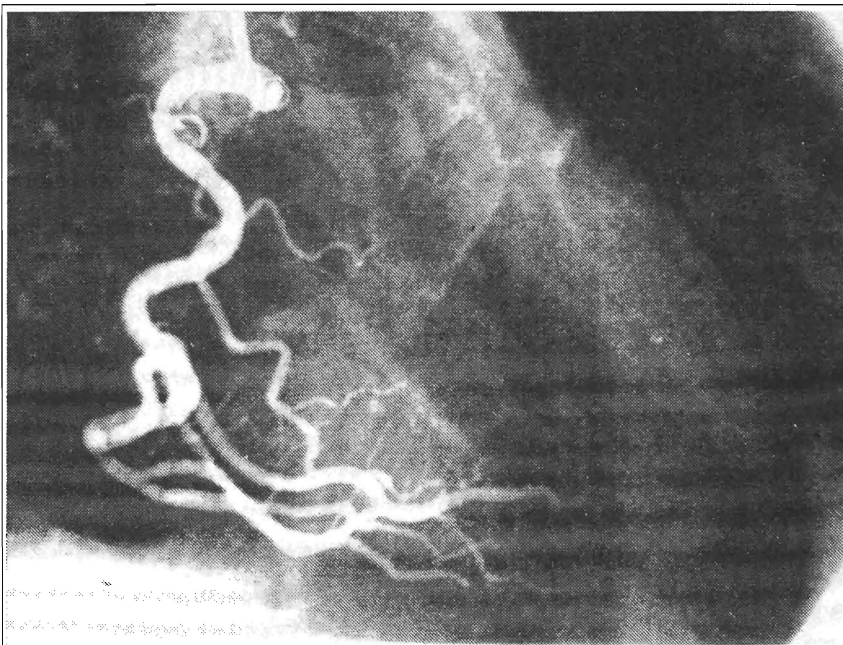


Figure 2. Right coronary angiogram showing the presence of a duplicate posterior descending coronary artery. (a) Spontaneous spasm at origin of both branches. (b) Spasm was relieved following intracoronary nitroglycerin.

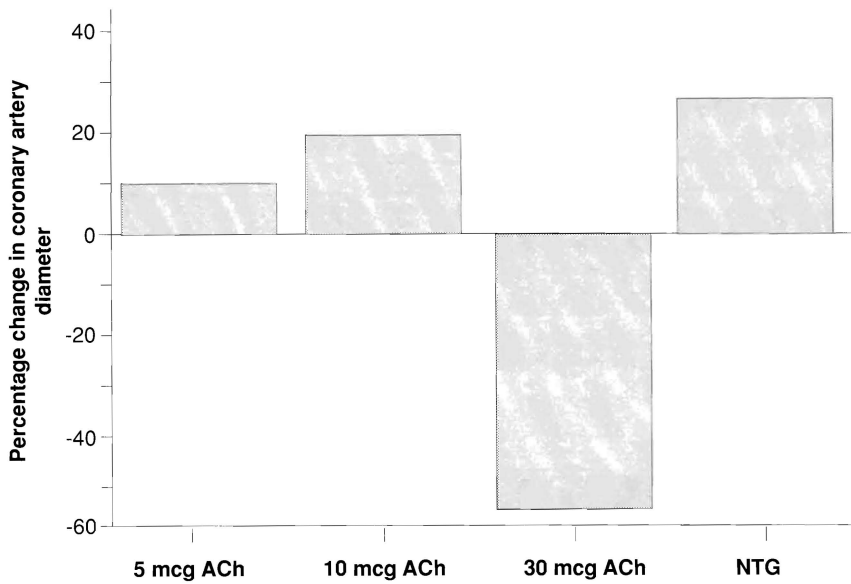


Figure 3. Percentage change in proximal left anterior descending coronary artery diameter in a patient with variant angina and angiographically normal coronary arteries. Intracoronary acetylcholine (ACh) at a low dose of 30 micrograms causes a marked reduction in lumen calibre of 55%. This is relieved by intracoronary nitroglycerin (NTG).

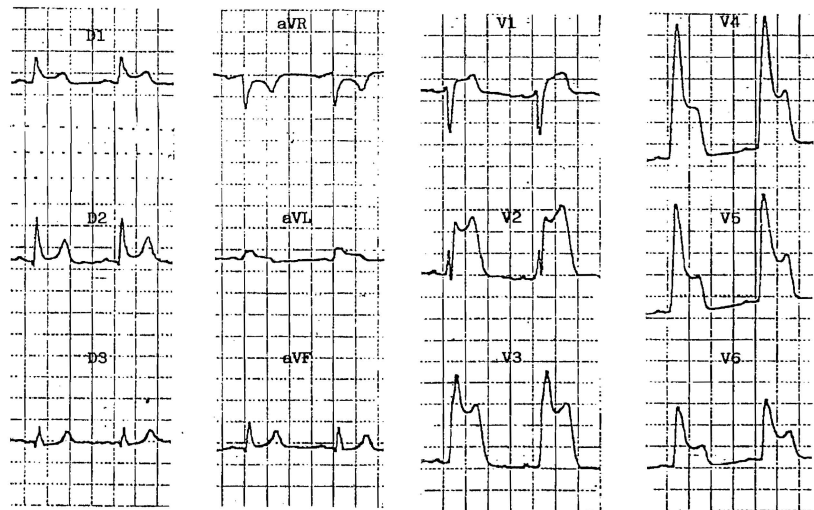
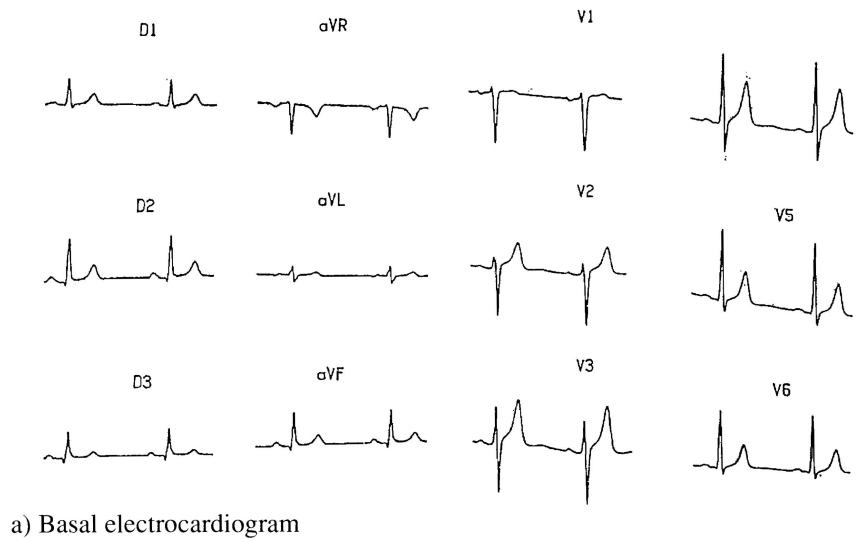


Figure 4. Basal electrocardiogram (a) and electrocardiogram recorded during hyperventilation testing (b) showing pronounced ST segment elevation in the anterolateral leads in a 53 year old male patient with documented spasm of the proximal left anterior descending coronary artery.

b) Electrocardiogram after hyperventilation

### Cardiac catheterization

Once suspected, a definite diagnosis of coronary artery spasm should be made during coronary angiography after careful withdrawal of therapy. Visualization of spasm causing coronary obstruction with resolution following intracoronary nitroglycerin is the gold standard for diagnosis (Figure 2). The location and degree of spasm, the number of vessels involved and the relationship to underlying fixed stenosis are defined. This is important to provide baseline information for later evaluation of therapy and disease activity. If a spontaneous ischaemic episode fails to occur during cardiac catheterization, provocative testing should be performed.

### Provocative Testing

Provocative testing is useful in those patients whose clinical manifestations are suggestive of the presence of coronary artery spasm, especially if normal or near normal coronary arteriograms are present. As it carries a 4.5% risk of arrhythmias in patients with provoked spasm, such testing should be carried out in the catheterization laboratory. This permits the documentation of changes in coronary artery diameter and allows the immediate use of intracoronary nitroglycerin if necessary. Provocative testing is absolutely contraindicated in the presence of severe hypertension, severe left ventricular dysfunction, severe aortic stenosis and significant left main stem disease.

*Ergonovine Test.* This highly sensitive and specific test is the most widely used for the provocation of coronary artery spasm. Ergonovine, an ergot alkaloid, stimulates both alpha-adrenergic and serotonergic receptors and therefore exerts a direct constrictive effect on vascular smooth muscle. Ergonovine produces chest pain with ST segment elevation in the vast majority of patients with variant angina who are in the active phase of the disease. Spasm is reversed by prompt intracoronary nitroglycerin.

*Acetylcholine.* A recent study by

Okumara et al<sup>26</sup> has shown that intracoronary acetylcholine is 90% sensitive and 99% specific for the provocation of spasm in patients with variant angina (Figure 3). The advantage of this agent is that the response is very transient and reverses spontaneously within 20 to 30 seconds. However the procedure requires temporary right ventricular pacing as bradyarrhythmias may occur especially with injection of acetylcholine in the right coronary artery.

*Hyperventilation.* The effect of systemic alkalosis in provoking coronary artery spasm is well documented (Figure 4). Hyperventilation is less sensitive than ergonovine in the induction of spasm but is less risky and may be used to provoke milder degrees of spasm.

## TREATMENT

The medical therapy for coronary artery spasm is still relatively nonspecific as the mechanisms that lead to spasm are still not fully understood. The effect rather than the cause is treated. The calcium antagonists, either alone or in combination with long-acting nitrates, are the cornerstones of treatment.

## MANAGEMENT OF THE ACUTE PHASE

Spasm-related ischaemia is treated with sublingual nitroglycerin. If this fails to control the anginal episode, intravenous nitroglycerin is given. The dose should be titrated in order to achieve resolution of symptoms and re-establishment of the basal electrocardiogram. Care should be taken to avoid hypotension and tachycardia as these may worsen ischaemia. Coronary spasm is usually very sensitive to nitrates, which act directly on the vascular smooth muscle leading to coronary vasodilation in a manner similar to EDRF. In the rare instances when spasm proves to be refractory to nitrates, a calcium antagonist may be added intravenously. The choice of the calcium blocker should be made depending on the presence or absence of bradyarrhythmias and left ventricular dysfunction.

## PREVENTION OF RECURRENCES

Intravenous nitrate therapy should be continued for some time after the patient has become symptom-free, keeping in mind the problem of tolerance and concurrently starting oral calcium antagonist therapy. Verapamil, nifedipine, diltiazem and the new dihydropyridines nicardipine and nisoldipine have all been demonstrated to be clinically efficacious. The dose should be tailored according to the individual patient. During flares of ischaemia, the dose should be increased to the maximum tolerated. Since different calcium channel blockers have a different mechanism on intracellular calcium movement, it seems warranted to try another agent if one calcium channel blocker does not induce a satisfactory clinical response at an appropriate dosage. Simultaneous administration of two antagonists may be required in some patients who remain symptomatic despite maximum tolerated doses of a single drug.<sup>27</sup>

## ASSESSING DRUG RESPONSIVENESS

Both initial and long-term therapies should be individualized according to duration and seriousness of the symptoms, markers of the disease activity, angiographic assessment of each patient and incidence of side effects. The most widely used method for evaluating the efficacy of therapy is ambulatory ECG monitoring. Some centres also use repeat catheterization and ergonovine provocative tests. When the patient has been symptom-free and with no objective evidence of spasm for 1 year, therapy may be withdrawn. In view of the possible occurrence of a rebound phenomenon on withdrawal of the calcium antagonists, a tapered withdrawal is advocated.<sup>28</sup> Since coronary artery spasm is a potentially life-threatening disease, the decision to withdraw therapy should not be made casually.

## OTHER TREATMENT MODALITIES

*General measures.* Factors which provoke spasm, particularly smoking, cold exposure and emotional stress, should be avoided.

*Beta-blockers.* Beta-blockade can theoretically worsen coronary spasm in patients with variant angina through blockade of coronary beta-receptors accompanied by unopposed alpha-receptor activity.<sup>29</sup>

*Aspirin.* Aspirin in high doses may actually increase the severity of ischaemia in Prinzmetal's angina by inhibition of the synthesis of prostacyclin.<sup>30</sup>

*Revascularization procedures.* Revascularization procedures are not indicated in patients with coronary artery spasm and normal coronary arteries. Coronary artery bypass grafting may be of some benefit in patients with recurrent spasm superimposed on severe atherosclerotic lesions. However, because of the possible occurrence of diffuse spasm, the results of surgery for this condition are not as good as the results in patients with angina and no evidence of spasm. If surgery is performed, coronary vasodilator therapy should be continued post-operatively. Similarly, percutaneous transluminal coronary angioplasty (PTCA) may be useful in a subgroup of patients with spasm on a haemodynamically important fixed atherosclerotic lesion, care being taken to avoid spasm during and after the procedure.

## NATURAL HISTORY AND PROGNOSIS

The natural history of coronary artery spasm remains largely speculative because treatment alters its outcome. It however appears to go through an acute active phase characterized by frequent episodes of angina with eventual remission of both symptomatic and asymptomatic ischaemia. Myocardial infarction and cardiac events are more likely to occur shortly after the initial presentation and in those patients in

whom spasm is superimposed on severe organic coronary lesions.<sup>31</sup> During the first six months, non-fatal myocardial infarction occurs in up to 20% of patients and death in up to 10%. Patients with coronary artery spasm and normal coronary arteries have a 5% risk for events, whereas those with severe multivessel disease have a 30% risk. Patients with arrhythmias during angina are also at a higher risk for sudden death.

## CONCLUSION

Careful history taking, continuous electrocardiographic monitoring and exercise stress testing remain the most practical means for diagnosing acute transient myocardial ischaemia.

Patients presenting with angina at rest, or effort angina with a variable threshold, are likely to have underlying coronary artery spasm. In such patients, an electrocardiogram taken during an episode of rest pain may clinch the diagnosis. These patients should be further investigated with coronary arteriography combined, if necessary, with provocative testing. Nitrates and calcium channel blockers appear at present to be the most effective drugs in the treatment of coronary artery spasm.

Acknowledgement

The authors thank Professor S.L. Chierchia MD, FACC, FESC, Director of the Department of Cardiology, Istituto Scientifico H. San Raffaele, Milan, for his invaluable help and advice.

## REFERENCES

1. Guazzi M, Fiorentini C, Plese A, Magrini F. Continuous electrocardiographic recording in Prinzmetal's variant angina pectoris. A report of four cases. *Br Heart J* 1970; 32: 611-616
2. Maseri A, Mimmo R, Chierchia SL, Marchesi C, Pesola A, L'Abbate A. Coronary artery spasm as a cause of acute myocardial ischaemia in man. *Chest* 1975; 68: 625-633
3. Chierchia SL, Brunelli C, Simonetti I, Lazzari M, Maseri A. Sequence of events in angina at rest: primary reduction in coronary flow. *Circulation* 1980; 61: 759-768
4. Maseri A, Severi S, De Nes DM, L'Abbate A, Chierchia SL, Marzilli M, Ballestra AM, Parodi O, Biagini A, Distante A. "Variant" angina: one aspect of a continuous spectrum of vasospastic myocardial ischemia. *Am J Cardiol* 1978; 42:1019
5. Wilson FN, Johnston FD. The occurrence in angina pectoris of electrocardiographic changes similar in magnitude and in kind to those produced by myocardial infarction. *Am Heart J* 1941; 22: 64
6. Prinzmetal M, Kenamer R, Merliss R, Wada T, Bor N. A variant form of angina pectoris. *Am J Med* 1959; 27: 375-388
7. Meller J, Pichard A, Dock S. Coronary arterial spasm in Prinzmetal's angina: a proved hypothesis. *Am J Cardiol* 1976; 37: 938-940
8. Numano F, Nomura S, Yajima M, Aizawa T, Fujii J, Kishida H, Hayakawa K, Sasuzuki T. Human leucocyte antigen in variant angina. *Int J Cardio* 1987; 14: 47-53
9. Yasue H, Touyama M, Kato H, Tanaka S, Akiyama F. Prinzmetal's variant form of angina is a manifestation of alphaadrenergic receptor-mediated coronary artery spasm. Documentation by coronaryarteriography. *Am Heart J* 1976; 91: 148-155
10. Chierchia SL, Davies G, Berkenboom G, Crea F, Crean P, Maseri A. Alpha-adrenergic receptors and coronary spasm: and elusive link. *Circulation* 1984; 69: 8-14

11. Robertson RM, Bernard YD, Can RK, Robertson D. Alpha-adrenergic blockade in vasotonic angina: Lack of efficacy of specific alpha<sub>1</sub>-receptor blockade with prazosin. *J Am Coll Cardiol* 1983; 2: 1146-1150
12. Yasue H, Horio Y, Makamura N, Fujii H, Imoto N, Sonodo R, Kugiyama K, Obata K, Morikami Y, Kimura T. Induction of coronary artery spasm by acetylcholine in patients with variant angina: possible role of the parasympathetic nervous system in the pathogenesis of coronary artery spasm. *Circulation* 1986; 74 (5): 955-963
13. Buda A, Fowles R, Schroeder J, Hunt S, Cipriano P, Stinson E, Harrison D. Coronary artery spasm in the denervated transplanted human heart. *Am J Med* 1981; 70: 1144-1149
14. Chierchia SL, De Caterina R, Crea F, Patrono C, Maseri A. Failure of thromboxane A<sub>2</sub> blockade to prevent attacks of vasospastic angina. *Circulation* 1982; 66: 702-705.
15. Chierchia SL, Patrono C, Crea F, Ciabottoni G, De Caterina R, Cinotti G, Distanti A, Maseri A. Effects of intravenous prostacyclin in variant angina. *Circulation* 1982; 65: 470-477
16. McFadden EF, Clarke JG, Davies GJ, Kaski JC, Haider AW, Maseri A. Effect of intracoronary serotonin on coronary vessels in patients with stable angina and patients with variant angina. *N Engl J Med* 1991; 324: 648-654
17. Freedman SB, Chierchia SL, Rodriguez-Plaza L, Bugiardini R, Smith G, Maseri A. Ergonovine-induced myocardial ischemia: no role for serotonergic receptors? *Circulation* 1984; 70: 178-183.
18. Forman M, Oates J, Robertson D, Robertson R, Roberts LJ, Virmani R. Increased adventitial mast cells in a patient with coronary spasm. *N Engl J Med* 1985; 313: 1138-1141
19. Okumara K, Yasue H, Matsuyama K, Morikami Y, Ogawa H, Olota K. Effect of H<sub>1</sub> receptor stimulation on coronary artery diameter in patients with variant angina: comparison with effect of acetylcholine. *J Am Coll Cardiol* 1991; 17: 338-345
20. Furchgott RF, Zawadski JV. The obligatory role of endothelial cells in relaxation of arterial smooth muscle by acetylcholine. *Nature* 1980; 288: 373-376
21. Macchi A, Xuereb RG, Xuereb M, Margonato A, Cianflone D, Vicedomini G, Chierchia SL. Role of atheroma and acute intimal injury on coronary vascular reactivity to acetylcholine and nitroglycerin (abstr). *Eur Heart J* 1991; 12: 6
22. Kaski JC, Maseri A, Vejar M, Crea F, Hackett D. Spontaneous coronary artery spasm in variant angina is caused by a local hyperreactivity to a generalized constrictor stimulus. *J Am Coll Cardiol* 1989; 14: 1456-1463
23. Nademanee K, Forelick DA, Josephson MA, Ryan MA, Wilkins JN, Robertson HA, Mody FV, Intarachot V. Myocardial ischaemia during cocaine withdrawal. *Ann Intern Med* 1989; 111: 876-880
24. Maseri A, L'Abbate A, Baroldi G, Chierchia SL, Marzilli M, Ballestra AM, Severi S, Parodi O, Biagini A, Distanti A, Pesola A. Coronary vasospasm as a possible cause of myocardial infarction: a conclusion derived from the study of "preinfarction" angina. *N Engl J Med* 1978; 299: 1271-1277
25. Hackett D, Davies G, Chierchia SL, Maseri A. Intermittent coronary occlusion in acute myocardial infarction. *N Engl J Med* 1987; 317: 1055-1059
26. Okumara K, Yasue H, Matsuyama K, Goto K, Miyagi H, Ogawa H, Matsuyama K. Sensitivity and specificity of intracoronary injection of acetylcholine for the induction of coronary artery spasm. *J Am Coll Cardiol* 1988; 12: 883-888
27. Prida ZE, Gelman JS, Feldman RL, Hill JA, Pepine CJ, Scott E. Comparison of diltiazem and nifedipine alone and in combination in patients with coronary artery spasm. *J Am Coll Cardiol* 1987; 9: 412-419
28. Schick EC Jr, Liang C, Heupler FA Jr, Kahl FR, Kent KM, Kerin NZ, Noble RJ, Rubenfire M, Tabatznik B, Terry RW. Randomized withdrawal from nifedipine: Placebo-controlled study in patients with coronary artery spasm. *Am Heart J* 1982; 104: 690-697
29. Robertson R, Wood A, Vaughan W, Robertson D. Exacerbation of vasotonic angina pectoris by propranolol. *Circulation* 1982; 65: 281-285
30. Miwa K, Kambara H, Kawai C. Effect of aspirin in large doses on attacks of variant angina. *Am Heart J* 1983; 105: 351
31. Severi S, Davies G, Maseri A, Marzullo P, L'Abbate A. Long-term prognosis of "variant" angina with medical treatment. *Am J Cardiol* 1980; 46: 226-232



The copyright of this article belongs to the Editorial Board of the Malta Medical Journal. The Malta Medical Journal's rights in respect of this work are as defined by the Copyright Act (Chapter 415) of the Laws of Malta or as modified by any successive legislation.

Users may access this full-text article and can make use of the information contained in accordance with the Copyright Act provided that the author must be properly acknowledged. Further distribution or reproduction in any format is prohibited without the prior permission of the copyright holder.

This article has been reproduced with the authorization of the editor of the Malta Medical Journal  
(Ref. No 000001)