

Bone Graft Stabilisation with an Osseointegrated Implant Retained Prosthesis

Simon Camilleri, Mark Diacono

Abstract

The intricacies of cleft lip and palate treatment are numerous. A case is reported where a problematic alveolar bone graft was finally stabilized by loading the bone with an osseointegrated implant-retained prosthesis. The reasons for failure of the previous grafts are discussed and the importance of a team approach to patient care highlighted.

Introduction

Cleft lip and palate (CLP) is one of the most common types of congenital malformation.

Cleft lip is caused by failure of fusion of the median and lateral nasal processes while cleft palate (CP) is caused by failure of fusion of the palatal shelves of the maxillary process. The mean incidence of orofacial clefts locally over the past 10 years is 0.2%.¹

The aetiology of CLP is multifactorial with both genetic and environmental factors playing a role. In recent years, a number of significant breakthroughs have occurred with respect to the genetics of these conditions, in particular, characterization of the underlying gene defects associated with several important clefting syndromes. The genetics of CLP has been reviewed by Coburne.²

Immediately after birth, individuals with CLP may have feeding problems and frequent middle ear infections. At the age of speech acquisition, speech therapy is often needed to correct problems resulting from muscular defects as a result of the cleft.³

Keywords

Cleft lip and palate, bone graft, orthodontics, osseointegration, implants

Simon Camilleri MSc, MOrthRCS(Eng) *
Faculty of Dental Surgery, University of Malta,
Dental School, Gwardamangia, Malta
Email: xmun@onvol.net

Mark Diacono BDS, FDSRCS(Eng)
Dental and Implantology Unit, St James Hospital, Sliema, Malta

* corresponding author

As the individual continues to grow, defects in tooth development and malocclusion often require dental and surgical treatment. The lengthy series of multidisciplinary treatments from birth to adulthood is a heavy burden for both the patient and family.

Lip and palate repair are generally carried out at three and nine months of age respectively. The scarring consequent to these procedures has been shown to retard maxillary growth⁴ and cause collapse and crowding of the upper dental arch.⁵ Delaying surgery has not been proved to have a beneficial effect on facial growth unless delayed until 12 years of age⁶ and then has permanently deleterious effects on speech⁷, apart from the obvious social problems.

Bone grafting of cleft lip and palate dento-alveolar defects is well researched and documented. The main aims of bone grafting are the following:

- close the oro-nasal fistula
- establish a continuous dentoalveolar process
- stabilize the premaxilla
- allow natural eruption of teeth into the area
- facilitate orthodontic movement of teeth
- support and elevate the lip, alae and nasal tip⁸

Van de Meij *et al*⁹ reported that the average cleft width is 6.4mm (range 3.0 to 12.2mm in their study) and that, on average, 64% of the initial graft remained after one year. Bone may be harvested from a variety of sites, the most common of which is the iliac crest. This has been reported to give superior results in larger cleft defects¹⁰ compared to cranial grafts.

Secondary alveolar bone grafts are ideally carried out between nine and eleven years of age just before the maxillary canine starts to descend. Eruption of this tooth into the graft loads the bone, stabilizes it and ensures success.¹¹ The teeth in the line of the cleft, notably the lateral incisor, are usually absent or of such poor quality as to necessitate their extraction. The ideal treatment would be to move the remaining teeth orthodontically into the graft so as to mask the resultant space. Should this prove impossible, the graft should be able to house dental implants for prosthetic replacement of these teeth.

Orthodontic expansion of the upper arch and alignment of the teeth may be carried out relatively easily. However the result must be retained artificially on a permanent basis as the tension of the scar tissue resulting from palate closure will cause relapse. As artificial teeth are often necessary to replace missing/poor

quality teeth, this type of retention is usually incorporated into the design of the prosthesis.

We present a case report of a thrice-grafted cleft, its eventual stabilization with osseointegrated titanium implants and the prosthetic replacement of missing teeth.

Case Report

The patient was referred from a major UK Cleft Lip and Palate centre. He presented as a 12 year old Caucasian male, born with a complete cleft of the hard and soft palate and a cleft of the left side of the lip and alveolus. The lip repair had been carried out shortly after birth and the palate repair at approximately 9 months.

He presented with a Class III incisor relation on a mild Class III skeletal base. The oral hygiene was poor and he required restoration of the upper left first molar. The upper left lateral incisor and upper left second premolar were congenitally absent. The upper left canine had erupted into the palate. Both lower first premolars had been previously extracted for orthodontic reasons (Figure 1a,b).

He gave a history of previous orthodontic treatment in preparation for a primary alveolar bone graft, carried out at another Centre in the UK. This first graft, taken from the tibia, had sequestered with consequent re-establishment of an oro-antral fistula. A repeat graft was being considered by the referring Cleft Lip and Palate team and he required further orthodontic treatment as part of his long term care. As orthodontic treatment requires frequent regular visits, it would be in the patient's interest to have this carried out locally.

The graft was carried out in January 1998 using bone taken from the iliac crest. This was successful, however the patient did not present for fitting of his upper and lower fixed orthodontic appliances until October 1999. The aims of the orthodontic treatment were to align the teeth, improve the molar and premolar occlusion and localize the space in the upper left

lateral incisor area in preparation for a prosthesis. This was completed in May 2001.

Again, a hiatus in treatment occurred and the patient was not reviewed in the UK until October 2001. By this time the bone graft had resorbed considerably (Figure 2a,b). The recommendation of the UK Cleft Lip and Palate team was that a third graft be carried out and osseointegrated implants placed after a suitable period of healing. Once osseointegration was established, bridgework could be placed, together with a palatal bar to maintain the shape of the upper arch. Again regular frequent visits would be necessary so the patient opted to have all the treatment carried out locally.

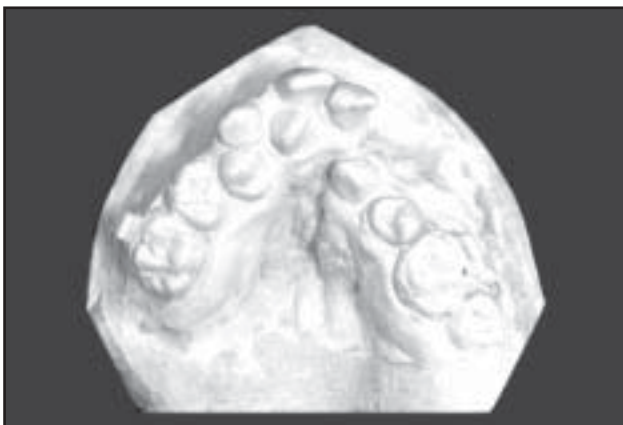He was referred for assessment and placement of the bone graft in October 2002. Initial clinical and radiographic examination revealed a partially successful alveolar bone graft. There was no oro-nasal communication. The height and width of the grafted alveolus was inadequate for implant treatment and the keratinized soft tissue was reduced over the edentulous space. Extensive scarring was evident in the area due to previous surgery.

Surgical treatment

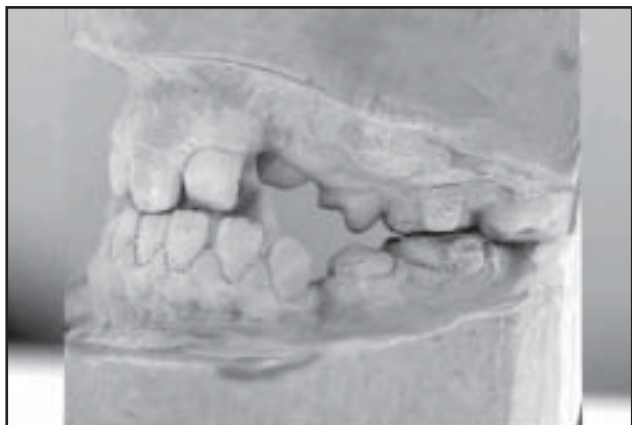The treatment plan was to graft bone to the cleft site and place two implants to support a bridge and orthodontic retainer. It was obvious that it would be difficult to replace all the missing bone in a single procedure due to limited availability of soft tissue for advancement over the grafted bone. As he had a low smile line, showing little of his teeth, pink porcelain was used on the bridgework to minimize the graft size and compensate for the lack of bone.

Impressions and occlusal records (bite registration and facebow) were taken and study models mounted onto a Denar® articulator. A full wax up and surgical stent was produced in the laboratory to help guide the quantity and position of the bone graft.

Figure 1: Prior to Orthodontic treatment, 17 months after placement of second graft:

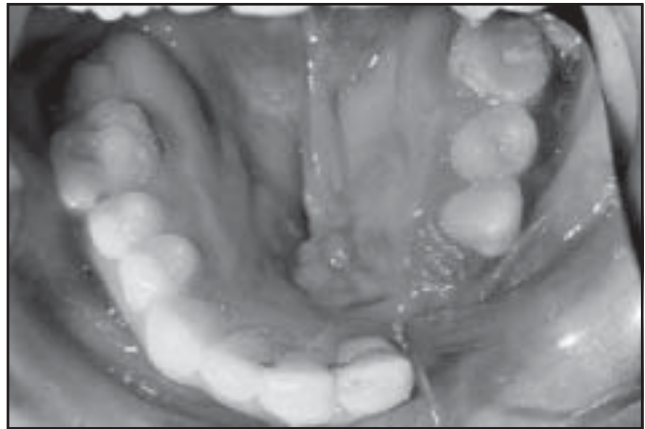
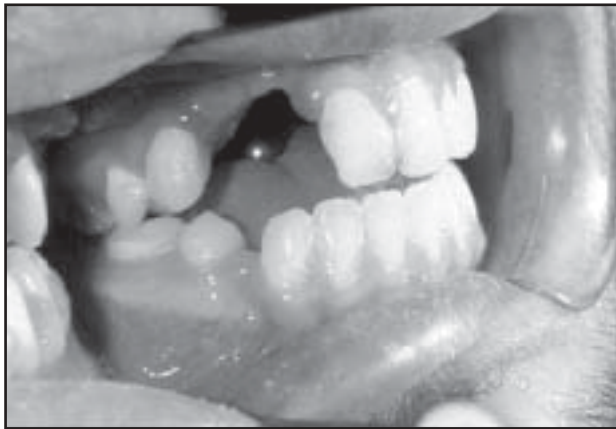

a) Occlusal view of the upper arch showing severe crowding and arch distortion. The waisting of the alveolus in the left lateral incisor region is evident



b) Left buccal view showing lack of contact of canine and premolar teeth

Figure 2: a) and b) Left Buccal and Occlusal mirror shots of arches post-orthodontics showing the gross alveolar defect



In late November 2002, he had bone harvested from his iliac crest and fixed to his maxilla under general anaesthesia and IV antibiotic cover (Augmentin® 1.2g).

A large buccally based three sided full thickness flap was raised from the right central incisor to the left premolar area. The recipient site was cleaned of all soft tissue remnants and the buccal plate perforated to allow bleeding from the marrow. A defect measuring 2 x 2 cm was noted (Figure 3a). Following routine skin preparation over the right iliac crest, a corticocancellous J-graft was harvested using a combination of drill / chisels. The J-Graft was shaped to fit the defect and secured with 2 X 8mm A-O screws® to achieve adequate stability (Figure 3b). To reduce resorption, a double layer of semi-permeable membrane (Biogide®, Geistlich, Wolhusen, Switzerland) was placed over the graft. This was secured with Frios® (Friadent-Schutze, Linz, Austria) membrane tacks. The periosteum was released and the flap advanced over the graft site. 3/0 Vicryl® was used to close the operative site intra-orally in a tension free manner. The donor site was closed in three layers, 2/0 Vicryl® to the periosteum, 3/0 Vicryl® to subcutaneous tissues/ fat and 3/0 Prolene to the skin. A subcutaneous line (Braun® epidural catheter) was secured in the area to administer analgesia postoperatively (Bupivacaine

0.25% with adrenaline 1:100,000). Augmentin®, 625mgs twice daily for a week and chlorhexidine 0.2% mouthwash was prescribed.

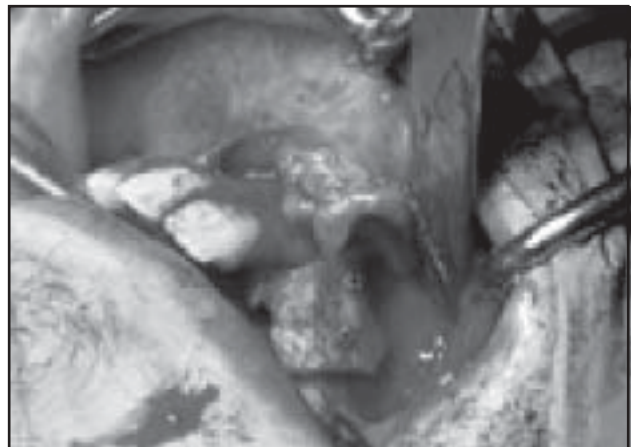
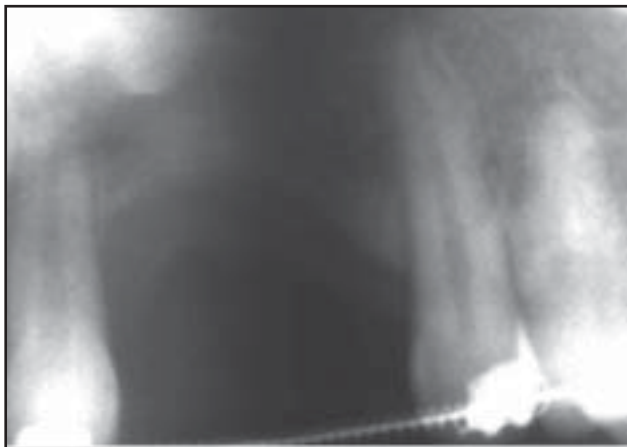
Sutures were removed one week later from both the oral and iliac crest surgical sites. A vacuum formed (Essix®) retainer reinforced with a 0.9mm steel bar was fitted to prevent the arches from collapsing. This was lined with Viscogel® tissue conditioner and had two acrylic teeth with a pink flange incorporated in the design.

Four weeks post-operatively, a 3mm exposure of the graft on the buccal aspect adjacent to the upper left central incisor was noted. Under local anaesthesia, an inferiorly based laterally rotated gingival flap was employed to close the defect. This was closed with 5/0 Ethilon®. These sutures were removed a week later.

Three months afterward, the patient developed an infection around one of the retention screws. He was placed on Clindamycin 300mgs twice daily for a week and had the screws removed under local anaesthesia. The graft had integrated well and there was only minimal resorption.

In early May 2003, under local anaesthesia and intravenous sedation, two (11.5mm and 13mm) Brånemark TiUnite® mark IV implants (Nobel Biocare, Gothenburg, Sweden) were inserted

Figure 3: a) Radiographic view of alveolar defect, b) J-Graft harvested from iliac crest secured with A-O screws.



into the graft (Figure 4). A surgical stent was used to guide the implants into the correct prosthetic position. Jaw bone quality was recorded as type III. Healing abutments were connected to the implants (single stage surgery) and the orthodontic retainer was adjusted to prevent the implants being indirectly functionally loaded.

Prosthetic treatment

Three months later, two Brånemark 1mm Multi-Unit abutments were connected to the implants and impressions/jaw registration taken. A temporary acrylic bridge was constructed on titanium multi-unit temporary cylinders and fitted. The orthodontic retainer was adjusted and reseated.

A wax pattern was built up onto two Multi-Unit gold cylinders. The gold framework was designed to incorporate a removable orthodontic retainer extending from left to right first molars. This was secured with a small screw (Briadent, Italy) on the palatal aspect of the framework (Figure 5a). The framework also supported both gingival and tooth coloured ceramic (Creation Ceramics, Zurich, Switzerland). A metal try-in verified the fit, followed by a ceramic try-in (biscuit bake) and finally an appointment to deliver the bridge and retainer (Figure 5b) The prosthesis was designed to be free from occlusal contact (but in line with his natural teeth). Oral hygiene instruction was given. The patient has been followed to date without any problems.

Discussion

The placement of implants into grafted bone is now well accepted treatment. The use of autogenous bone is classed as the gold standard¹², however other bone products such as Bio-Oss® (Geistlich, Wolhusen, Switzerland) or Biogran® are widely used with very good success rates, thus reducing or eliminating the morbidity of the donor site.^{12, 13} For smaller defects, autogenous bone is normally harvested from the peri-implant site, mental region, maxillary tuberosities or ascending rami of the mandibles. Larger grafts are harvested from various

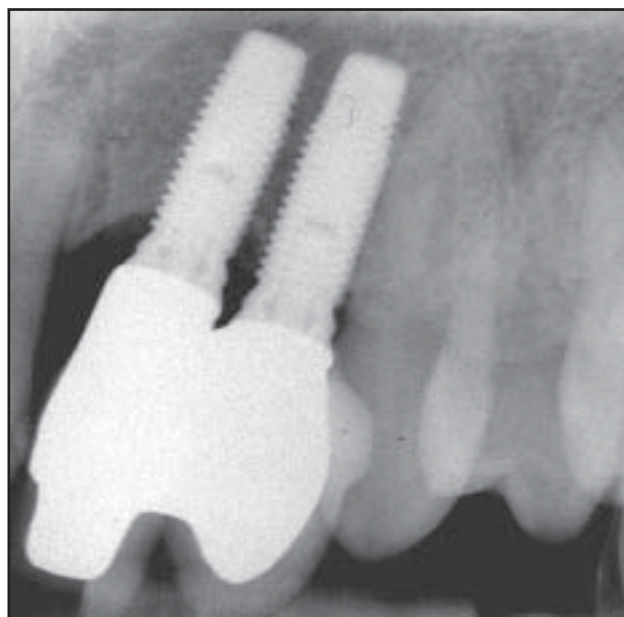
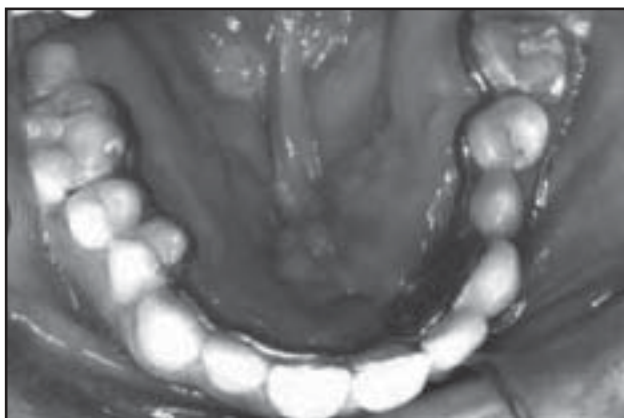


Figure 4: Post-implant radiograph showing maintenance of alveolar height

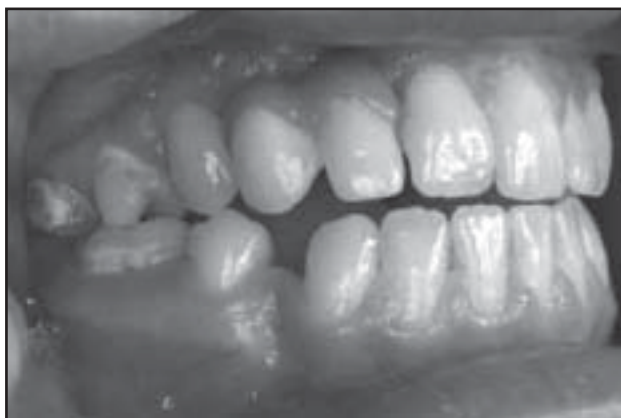extra-oral sites, the most common being the iliac crest. A J-graft is normally employed when both height and width of the residual alveolus require augmentation thus giving the graft a dense cortical surface on its exposed surfaces. Furthermore, in the future, it may be possible to move teeth orthodontically into defects restored with xenografts, thus minimizing the morbidity of this type of surgery.¹⁴

Alveolar bone is a functional process, dependent on the presence of teeth for its existence. Bone grafted to the alveolar process acts as alveolar bone, irrespective of the donor site. Loading of the bone through the roots of the teeth or embedded osseointegrated implants has an osteogenic effect, maintaining the bone. Osteocytes are considered to be the cells responsible for this role because of their syncytial distribution throughout the bone matrix and their ability to respond to strain.¹⁵

Figure 5: The prosthesis in place



a) palatal bar placed to maintain arch expansion



b) buccal view showing restoration of appearance

Mechanical loading of bone not only deforms the bone tissue, but also engenders movement of extracellular fluid through the bone's lacuno-canalicular system. Such fluid flow may stimulate bone cells via streaming potentials, wall shear stress, or chemotransport related effects^{16,17} Release of prostaglandins by osteocytes¹⁸ and nitric oxide¹⁹ by both osteoblasts and osteocytes stimulates bone response to mechanical stimulation. Lack of function will allow resorption of bone due to decreased bone formation.^{20,21}

The failure of the original graft may have been partly due to the difficulty in close supervision of the patient's oral hygiene immediately prior to the graft. The surgeon's report mentions poor oral hygiene in association with an acrylic orthodontic retainer. The resultant inflamed, friable mucosa led to difficulties in satisfactory wound closure and subsequent rejection.

The resorption of the second graft was certainly due to a hiatus in communication between the two centres and the patient. This resulted in a delay between placement of the second graft and commencement of orthodontic treatment, allowing the graft to resorb to the point that orthodontic movement of the canine into the graft may have compromised the status of the canine which had erupted into the palate prior to the second graft.

The unloaded alveolar bone continued to resorb during orthodontic treatment, to the extent that a fresh graft became necessary to provide bone for implant placement.

The common thread associated with failure of both first and second grafts seems to be due to the patient receiving long term care shared between two widely distanced centres. In respect of the third graft, close communication between the two operators ensured the patient was kept under continual supervision and that co-operation did not flag to the extent that treatment was compromised.

Conclusion

Cleft lip and palate treatment involves a large number of specialities. Speech therapists; plastic, maxillofacial and ENT surgeons; orthodontists, paediatric and restorative dentists are all intensely involved in the care of these children. The formation of a team of specialists who will regularly review these patients on joint clinics in order to plan and synchronise treatment and keep in close communication is an essential part of today's method of care. There is a direct relationship between volume of work and outcome.²² Consequently the formation of a local Cleft Lip and Palate team, which deals with all registered cases, has been a substantial step forwards in co-ordination and improvement in patient care and saving of both professional and patient time and travel.

Reference

- 1 Congenital Anomalies Register - Department of Health Information Unit.
- 2 Cobourne MT. The complex genetics of cleft lip and palate. *Eur J Orthod* 2004; 26(1):7-16.

- 3 Watson ACH, Sell DA, Grunwell P. Management of cleft lip and palate. London : Whurr, 2001.
- 4 Capelozza FL, Normando AD, Silva Filho OG. Isolated influences of lip and palate surgery on facial growth: comparison of operated and unoperated male adults with UCLP. *Cleft Palate Craniofac J* 1996; 33(1):51-56.
- 5 Dahl E, Hanusardottir B, Bergland O. A comparison of occlusions in two groups of children whose clefts were repaired by three different surgical procedures. *Cleft Palate J* 1981; 18(2):122-127.
- 6 Witzel MA, Salyer KE, Ross RB. Delayed hard palate closure: the philosophy revisited. *Cleft Palate J* 1984; 21(4):263-269.
- 7 Bardach J, Morris HL, Olin WH. Late results of primary veloplasty: the Marburg Project. *Plast Reconstr Surg* 1984; 73(2):207-218.
- 8 Turvey TA, Hegtvedt AK. Surgical correction of craniofacial malformations. *J Oral Maxillofac Surg* 1993; 51(1 Suppl 1):69-81.
- 9 van der Meij AW, Baart JA, Prah-Andersen B, Kostense PJ, van dS, Jr., Tuinzing DB. Outcome of bone grafting in relation to cleft width in unilateral cleft lip and palate patients. *Oral Surg Oral Med Oral Pathol Oral Radiol Endod* 2003; 96(1):19-25.
- 10 LaRossa D, Buchman S, Rothkopf DM, Mayo R, Randall P. A comparison of iliac and cranial bone in secondary grafting of alveolar clefts. *Plast Reconstr Surg* 1995; 96(4):789-797.
- 11 Bergland O, Semb G, Abyholm FE. Elimination of the residual alveolar cleft by secondary bone grafting and subsequent orthodontic treatment. *Cleft Palate J* 1986; 23(3):175-205.
- 12 Simion M, Fontana F. Autogenous and xenogeneic bone grafts for the bone regeneration. A literature review. *Minerva Stomatol* 2004; 53(5):191-206.
- 13 Valentini P, Abensur D, Wenz B, Peetz M, Schenk R. Sinus grafting with porous bone mineral (Bio-Oss) for implant placement: a 5-year study on 15 patients. *Int J Periodontics Restorative Dent* 2000; 20(3):245-253.
- 14 Araujo MG, Carmagnola D, Berglundh T, Thilander B, Lindhe J. Orthodontic movement in bone defects augmented with Bio-Oss. An experimental study in dogs. *J Clin Periodontol* 2001; 28(1):73-80.
- 15 Noble BS, Peet N, Stevens HY, Brabbs A, Mosley JR, Reilly GC et al. Mechanical loading: biphasic osteocyte survival and targeting of osteoclasts for bone destruction in rat cortical bone. *Am J Physiol Cell Physiol* 2003; 284(4):C934-C943.
- 16 Duncan RL, Turner CH. Mechanotransduction and the functional response of bone to mechanical strain. *Calcif Tissue Int* 1995; 57(5):344-358.
- 17 Reich KM, Gay CV, Frangos JA. Fluid shear stress as a mediator of osteoblast cyclic adenosine monophosphate production. *J Cell Physiol* 1990; 143(1):100-104.
- 18 Klein-Nulend J, Burger EH, Semeins CM, Raisz LG, Pilbeam CC. Pulsating fluid flow stimulates prostaglandin release and inducible prostaglandin G/H synthase mRNA expression in primary mouse bone cells. *J Bone Miner Res* 1997; 12(1):45-51.
- 19 Klein-Nulend J, Helfrich MH, Sterck JG, MacPherson H, Joldersma M, Ralston SH et al. Nitric oxide response to shear stress by human bone cell cultures is endothelial nitric oxide synthase dependent. *Biochem Biophys Res Commun* 1998; 250(1):108-114.
- 20 Wronski TJ, Morey-Holton ER, Doty SB, Maese AC, Walsh CC. Histomorphometric analysis of rat skeleton following spaceflight. *The American Journal Of Physiology* 1987; 252(2, Part 2):R252-R255.
- 21 Lafage-Proust MH, Collet P, Dubost JM, Laroche N, Alexandre C, Vico L. Space-related bone mineral redistribution and lack of bone mass recovery after reambulation in young rats. *American Journal of Physiology - Regulatory Integrative and Comparative Physiology* 1998; 274(2 43-2):R324-R334.
- 22 Bearn D, Mildinhal S, Murphy T, Murray JJ, Sell D, Shaw WC et al. Cleft lip and palate care in the United Kingdom—the Clinical Standards Advisory Group (CSAG) Study. Part 4: outcome comparisons, training, and conclusions. *Cleft Palate Craniofac J* 2001; 38(1):38-43.