

'Twiddling' of the Pacemaker Resulting in Lead Dislodgement

Daniela Cassar DeMarco, Robert G. Xuereb

Abstract

Twiddler's syndrome is a rare condition in which patient manipulation of the pulse generator within its pocket may result in coiling of the lead and lead dislodgement, thereby causing pacemaker malfunction. Retraction of the electrode may cause phrenic nerve stimulation resulting in diaphragmatic stimulation and a sensation of abdominal pulsations. As the leads are further wrapped around the generator, rhythmic arm twitching may occur as a result of pacing of the brachial plexus.¹

Twiddler's syndrome was first described by Bayliss et al in 1968 as a complication of pacemaker implantation.² It has also been reported with implantable cardioverter-defibrillators (ICDs)³ and cardiac resynchronisation therapy (CRT).⁴

This is a case report of an elderly lady with Twiddler's syndrome resulting in pacemaker malfunction secondary to lead retraction, who emphatically denied any manipulation of her device. She subsequently underwent lead repositioning and appropriate counselling.

Keywords

Twiddler's syndrome, lead dislodgement, pacemaker malfunction

Daniela Cassar DeMarco * MD, MRCP
Cardiology Department, Mater Dei Hospital, Malta
Email: daniela.demarco@gov.mt

Robert G. Xuereb FRCP, FESC
Cardiology Department, Mater Dei Hospital, Malta

* corresponding author

Case Report

A 77 year old lady with a history of ischaemic heart disease and depression, presented with a three month history of fatigue. Examination revealed a heart rate of 40 beats per minute. The resting electrocardiogram (ECG) showed junctional rhythm alternating with sinus bradycardia and a heart rate of approximately 35 beats per minute. Electrolyte disturbances and hypothyroidism were excluded. A dual chamber pacemaker was implanted with appropriate lead parameters for sensing and pacing. The chest x-ray (CXR) after pacemaker implantation showed ideal atrial and ventricular lead positioning, with the pacemaker head pointing upwards and lead attachment to the left. A left-sided pneumothorax was present (Figure 1). Since this was large with a rim of air between lung margin and chest wall of >2 cms, a chest drain was inserted. The CXR performed after removal of the chest drain showed resolution of the pneumothorax and subcutaneous emphysema (Figure 2). A CXR taken 10 days after removal of the chest drain in order to check for recurrence of the pneumothorax showed full lung expansion. Although the pacemaker head was still pointing upwards, lead attachment was now situated to the right. Atrial lead pullback was also present (Figure 3).

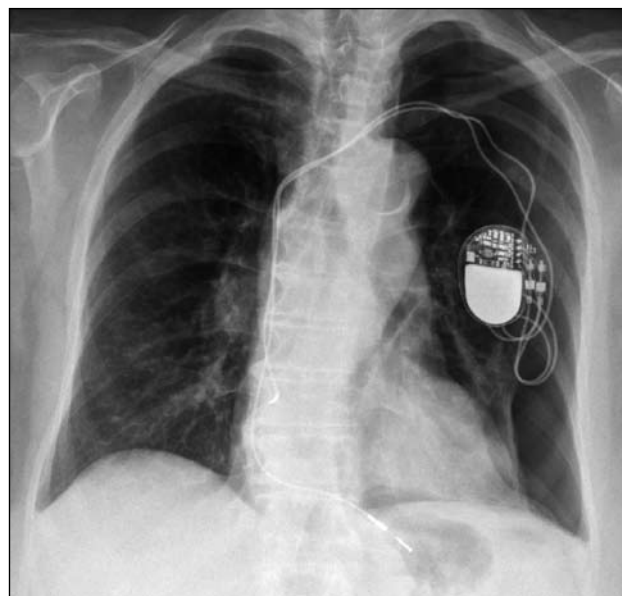


Figure 1: CXR after pacemaker insertion. A large pneumothorax is present. The pacemaker head is pointing upwards with lead attachment on the left

The patient presented 6 weeks after pacemaker implantation with abdominal and thoracic muscle twitching. The ECG showed sinus bradycardia with no pacing. The CXR now showed displaced and entangled atrial and ventricular leads, with the ventricular lead in the right atrium and the pacemaker head pointing downwards with lead attachment on the left (Figure 4). The patient denied any manipulation of the pacemaker.

Pacemaker lead repositioning was performed. During this procedure the leads were found to be grossly entangled into repeated knots (Figure 5), with the right ventricular lead

dislodged into the right atrium. The right atrial lead, although stretched, was still positioned in the right atrial appendage. The leads were checked and found to be intact. The patient remained well after lead repositioning. She was strongly advised to avoid further pacemaker manipulation.

Discussion

Twiddler's syndrome is an uncommon complication of pacemaker implantation. It should be considered as a cause of pacemaker failure in patients presenting with fatigue, syncope

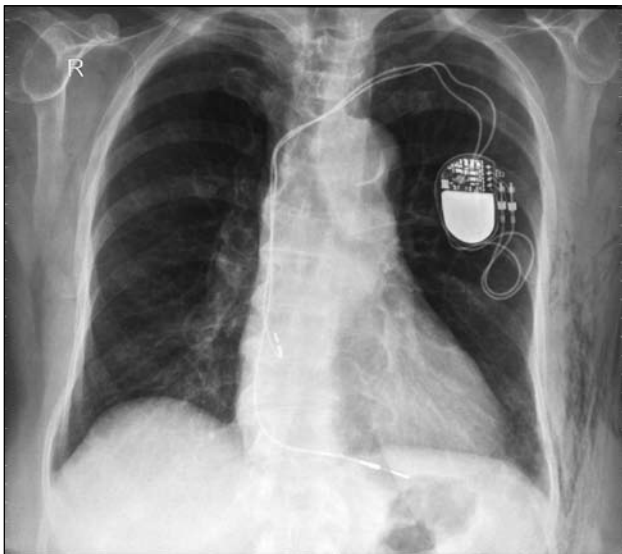


Figure 2: CXR after removal of chest drain showing resolution of the pneumothorax. Subcutaneous emphysema is present. Note that the atrial lead is pointing upwards in the right atrial appendage and the ventricular lead is pointing downwards towards the right ventricular apex

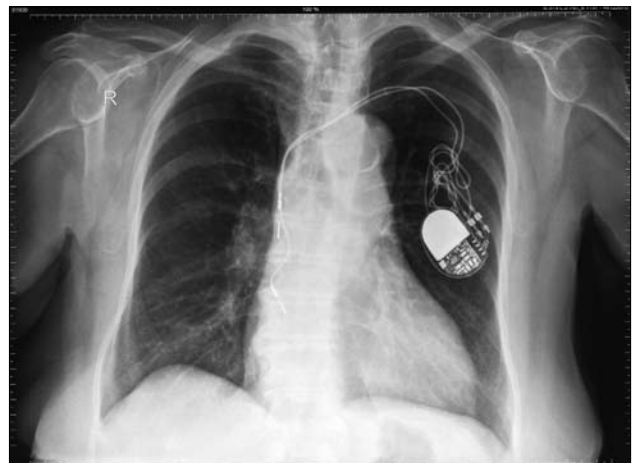


Figure 4: CXR showing displaced atrial and ventricular leads. The ventricular lead is in the right atrium. The leads are grossly entangled and the pacemaker head is pointing downwards with lead attachment on the left

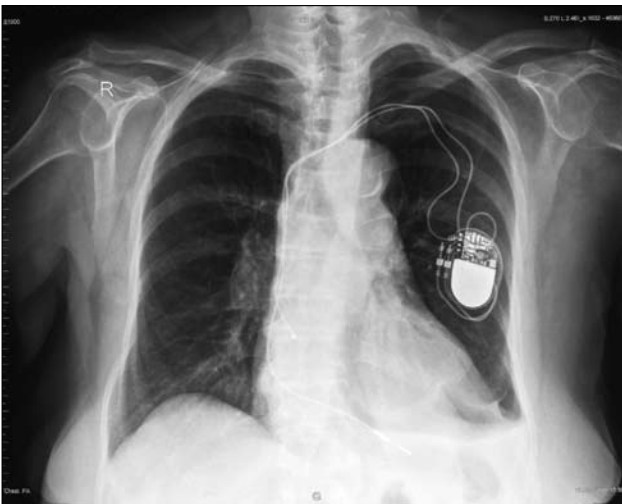

Figure 3: CXR taken 10 days after removal of chest drain. There is right atrial lead pullback and although the pacemaker head is still pointing upwards, lead attachment is now situated on the right

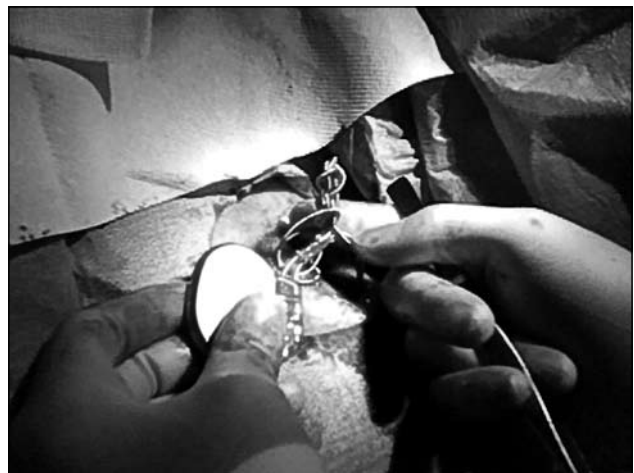


Figure 5: Grossly entangled leads during pacemaker lead repositioning

and dizziness post pacemaker implantation. Our patient presented with abdominal and thoracic muscle twitching as a result of phrenic nerve stimulation. The latter may also cause persistent hiccups. With further lead withdrawal, brachial plexus stimulation may result in arm twitching.¹

Most patients deny any manipulation of the device. Our patient had several risk factors associated with Twiddler's syndrome, namely obesity, old age, female gender and psychiatric illness. It is more common in elderly patients possibly due to laxity of subcutaneous tissues.³ However, it has also been reported in children.⁵ Another cause for rotation of the pacemaker is its small size relative to the pocket. As cognitive impairment is common among patients with congestive heart failure, patients receiving CRT are more likely to be at risk for developing Twiddler's syndrome.⁴

Twiddler's syndrome may remain asymptomatic in patients with ICD implantation. However, lead fracture or dislodgement in an ICD can cause inadequate shock deliveries, inappropriate therapy due to false sensing or even sudden cardiac death.^{6,7} Fixation of the pulse generator with a ligature during the implantation may prevent twiddling of the pacemaker. A tightly fitting pocket without redundant space around the generator and fixation of the pulse generator can be considered in patients with mental disorders, confusion or very lax subcutaneous tissues.⁸

The CXR is the most important and simplest diagnostic

tool. The majority of patients with Twiddler's syndrome are diagnosed within the first year of pacemaker implantation.⁹ Treatment includes uncoiling the lead, new lead implantation, and repositioning of the pulse generator. However, patient education remains the single most important means of avoiding pacemaker manipulation.

References

1. Nicholson WJ, Tuohy KA, Tilkemeier P. Twiddler's Syndrome. *N Engl J Med.* 2003;348:1726-27.
2. Bayliss CE, Beanlands DS, Baird RJ. The Pacemaker-Twiddler's Syndrome: A New Complication of Implantable Transvenous Pacemakers. *Canad Med Assoc J.* 1968;99:371-3.
3. Sharifi M, Inbar S, Neckels B, Shook H.. "Twiddling" to the Extreme: Development of Twiddler Syndrome in an Implanted Cardioverter-Defibrillator. *J Invasive Cardiol.* 2005;17:195-6.
4. Riezebos RK, de Ruiter GS. Twiddler's Syndrome: An Unusual Cause of Pacemaker Dysfunction. *Am J Geriatr Cardiol.* 2008; 17:53-4.
5. Abrams S, Peart I. Twiddler's Syndrome in Children: An Unusual Cause of Pacemaker Failure. *Br Heart J.* 1995; 73:190-2.
6. Mewis C, Kühnkamp V, Dörnberger V, Kalighi K, Seipel L. Lead Failure Caused by Twiddler's Syndrome in Subpectorally Implanted Unipolar Single-lead Cardioverter Defibrillators. *J Thorac Cardiovasc Surg.* 1997;114:1121-2.
7. Csanadi Z., Hegedus Z., Csanady M. Twiddler's Syndrome in a Patient with An Implantable-Cardioverter Defibrillator. *Heart.* 2006; 92:826.
8. Fahraeus T, Højjer CJ. Early Pacemaker Twiddler Syndrome. *Europace.* 2003 5:279-81.
9. Harel G, Georgeta E, Copperman Y. Twiddler's Syndrome: A Rare Cause of Pacemaker Failure. *IMAJ.* 2008;10160-1.

Corinthia Group Prize in Paediatrics, 2009

The Corinthia Group Prize in Paediatrics was awarded to Dr Ian Said, who obtained the highest aggregate mark over the combined examinations in Paediatrics in the fourth and final year of the undergraduate course. As always, competition for the Corinthia Group Prize was fierce, with ten candidates vying for the honour! Whilst offering our congratulations to Dr Said, we would also like to congratulate all those undergraduates (now doctors) who performed admirably during the undergraduate course in Paediatrics. In the accompanying photograph, Dr Said is seen receiving a cheque for €233 from Professor Simon Attard Montalto, Head of Paediatrics at the Medical School. Finally, the Academic Department of Paediatrics and Medical School remain indebted and are extremely grateful to the Corinthia Group for their ongoing support.

Professor Simon Attard Montalto

